ABDOMEN

❒ OVERVIEW

Transpyloric plane
- ½ btwn manubrium & pubic symphysis
- Transects: pylorus, gall bladder fundus, pancreatic duct, SMA, Portal vein, root transvers mesocolon, DJ jcn, hila kidney

❒ ANETROLATERAL ABDOMINAL WALL

- Sup: 7-10 ribs, xiphoid
- Inf: inguinal ligament, superior pelvic girdle

Fascia
- Different to rest of body below umbilicus
- 2 layers: superficial fatty vs deep membranous (Cont as superficial perineal fascia)
- Investing fascia around 3 layers of muscle (sup, int, deep)
- Transversus abdominus covered in transversalis fascia

Aponeurosis
- Form both intermuscular and intramuscular exchanges (btwn ext/int obliques)
- *Rectus sheath* is a condensation of all 3 aponeurosis on lateral border of rectus abdominus
  - Sup 2/3: ant: ext o, ant internal o vs post: int o, transversus
  - Inf 1/3: all ant (1/2 way down from umbilicus to rectus abdomen
  - Sup separated from inf by arcuate line
  - Aponeurosis of internal oblique encapsulates rectus abdominus
  - Also contains epigastric vessels, lymphatics, thoracoabdominal nerves
- *Linea Alba* is the condensation of all 3 aponeurosis after traversing rectus abdominus at midline, sup widens sup to width of xiphisternum, inf tightens
- Ext Oblique fascia forms inguinal ligament inferiorly (ASIS → pubic tubercle) which is cont as deep fascia of thigh

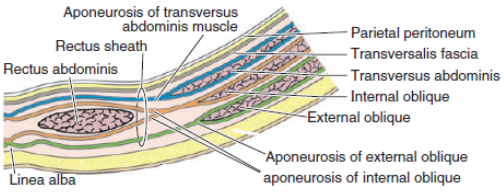

Muscles

External Oblique	Ext 5-12th rib	Linea alba Pubic tubercle Ant ½ iliac crest	T7-11 spinal Subcostal	
Internal Oblique	Thoracolumbar fascia Ant 2/3 iliac crest Lat 1/3 inguinal ligament	Inf 10-12th rib Linea alba Pectin pubis	Thoracoabdominal (ant rami T6-12, L1)	Compress viscera Flex/rotate trunk
Transversus Abdominus	Int 7-12th cart Thoracolumbar fascia Iliac crest Lat 1/3 inguinal ligament	Linea alba Internal oblique aponeurosis Pubic crest		Compress viscera
Rectus Abdominus	Pubic symphysis Pubic crest	Xiphoid process 5-7th cartilage	Thoracoabdominal (ant rami T6-12)	Compress viscera Flex (strong) Stabilise Draws down line alba
Pyramidalis	Pubic crest	Linea alba		

NB neurovascular plain between internal oblique & transversus abdominus (same as ribs)

Nerve

Thoracoabdominal (T7-11)	Cont of IC nerves distal to costal margin Runs btwn int o/transversus Form ant and lateral cutaneous branches Dist: muscles of anterolateral abdominal wall and skin
7-9th cutaneous	Cont of IC n. Dist: skin to hypochondriac region
Subcostal (T12)	Spinal T12 Runs inf border 12th rib Dist: muscles btwn umbilicus & iliac crest
Illiohypogastric (L1)	L1 ant ramus (sup terminal branch) Dist: skin on iliac crest, upper inguinal, hypogastric region muscle internal o. and transversus
Illioinguinal (L1)	L1 ant ramus (inf terminal branch) Dist: skin to lower inguinal, mons pubis, ant scrotum, labium major, media thigh Muscle: int o. (inf parts), transversus

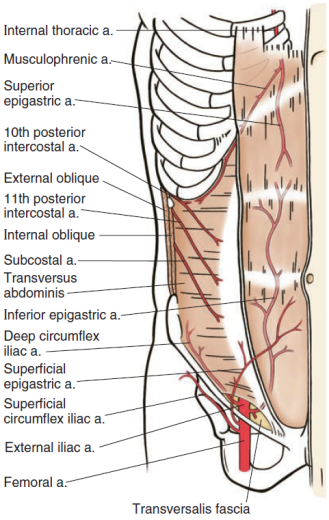

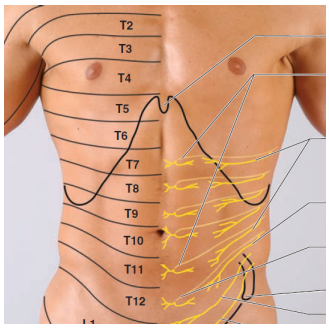

Neurovascular
Dermatomes
Follow ribs
T4 = nipple
T10 = umbilicus
L1 = inguinal fold

Vessels
Veins
- Superior: medial (internal thoracic), lateral (lateral thoracic)
- Inferior: superficial epigastric (→ femoral) or inferior epigastric (→ ext iliac) vein

Artery	Origin	Course
Musculophrenic	Internal thoracic	Costal margin Dist: all hypochondriac region & anterolateral diaphragm
Sup Epigastric		Descends in rectus sheath Dist: rectus abdominus, epigastric layers
10-11th post IC	Ao	Btwn internal/transversus
Subcostal		Dist: flank region
Inf epigastric	Ext Iliac	Ascends in rectus sheath post to rectus abdominus Dist: Rectus, deep wall of pubic/inf umbilical region
Deep circ iliac		Ant abdominal wall parallel to inguinal ligament Dist: Iliacus muscle, deep wall muscles, iliac fossa
Sup circ iliac	Femoral	SC tissue along inguinal ligament Dist: superficial wall muscles & ant thigh
Sup epigastric		SC tissue towards umbilicus Dist: superficial wall of pubic/inf umbilical region

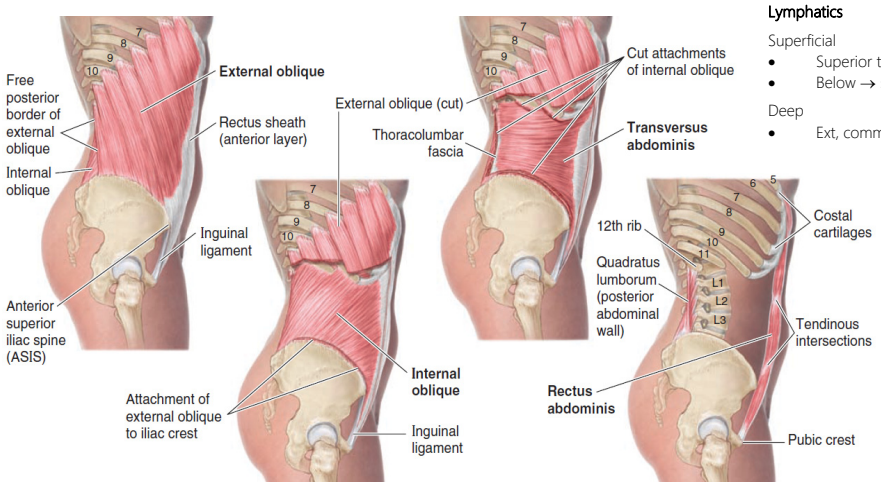

Lymphatics
Superficial
- Superior to *transumbilcal plain* → axillary (some parasternal)
- Below → superficial inguinal

Deep
- Ext, common iliacs and right & left lumbar nodes

ABDOMEN

❒ INTERNAL SURFACE OF ANTEROLATERAL WALL

- Transversalis fascia/Extra peritoneal fat/Parietal peritoneum
- Falciform ligament supraumbilical → round ligament of liver

5 infraumbilical peritoneal folds

1. Median: apex of bladder to umbilicus, covers median umbilical ligament
2. x2 medial umbilical folds: covers medial umbilical ligament (occluded umbi a.)
3. x2 lateral umbilical folds: cover inf epigastric vessels

Fossa	Location	Contents
Supravesicular	Median | Medial	
Medial Inguinal	Medial | Lateral	Direct Hernia
Lateral Inguinal	Lateral | wall	Deep Inguinal Ring/Indirect Hernia

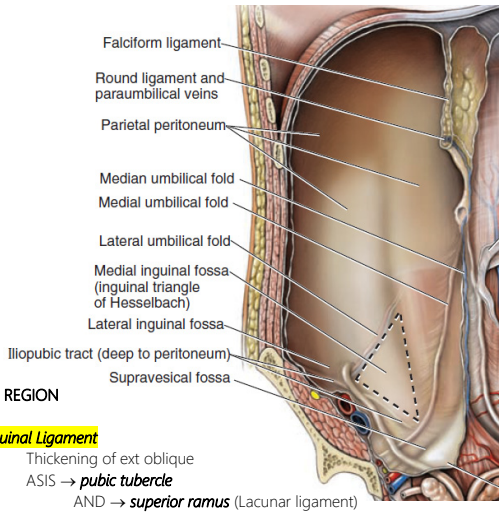

INGUINAL REGION

Inguinal Ligament

- Thickening of ext oblique
- ASIS → *pubic tubercle*
  - AND → *superior ramus* (Lacunar ligament)
  - AND → *pectin pubis* (Pectineal ligament)
  - AND → *reflected inguinal ligament* (top contralateral internal oblique

Iliopubic Tract

- Deep to inguinal ligament
- Reinforces back of ing lig
- Thickening of *transversalis fascia*

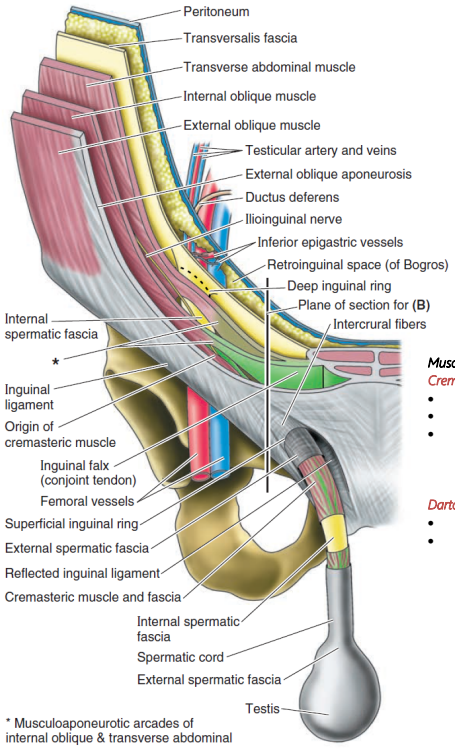

Muscles of Male Genitilia

Cremasteric

- Derivative of int oblique
- Draws testes upwards
- Striated (innervated by genital branch of Genitofemoral nerve (L1, 2 from lumbar plexus)

Dartos

- Within subcut scrotum
- Smooth muscle

Inguinal Canal

Deep inguinal ring

- Parallel and sup to medial 1/2 inguinal ligament
- *Ductus deferens* passes through to inguinal canal

Superficial Inguinal Ring

- Cont of *ext obliques*
- Crus come off medial (→ pubic crest) and lateral (→ tubercle) to anchor superficial ring

Boundary	*Deep Ring/Lateral 3rd*	*Middle 3rd*	*Medial 3rd*
Posterior Wall	Transversalis Fascia	Transversalis Fascia	Inguinal falx[2] & ligament
Anterior Wall	Ext Oblique[1]+ Int Oblique	Ext Oblique[1]	Ext Oblique[1]/Ext spermatic fascia
Roof	Transversalis fascia	Musculoaponeurotic arch[4] & transverse abdominal	Medial crus[3]
Floor	Iliopubic tract	Inguinal ligament	Lacunar ligament

[1]Aponeurosis
[2]Merging of internal oblique and transversalis aponeurosis
[3]Of External oblique aponeurosis
[4]Of internal oblique

Spermatic Cord

Fascias	*Abdominal Derivative*
Internal Speramatic Fascia	Transversalis Fascia
Cremasteric Fascia	Sup & Deep internal oblique fascia
External Spermatic Fascia	External oblique aponeurosis

Content	
Ductus Deferens	Epididymis → ejaculatory duct
Testicular Artery	From Ao
Artery of Ductus Deferens	From inferior vesicular
Cremasteric Artery	From inferior epigastric
Pampiniform venous plexus	→ testicular veins
Nerve fibres	Sympth to a. para/sympth to ductus
Genital branch of Genitofemoral nerve	To Cremasteric muscle
Lymphatic Vessels	→ lumbar nodes
Vestige of processus vaginalis	Fibrous cord ant to Speramatic cord

Scrotum

Wall

- Pigmented Skin
- *Dartos fascia* → septum of scrotum
  - Cont sup-ant as *Scarpa fascia*
  - Cont sup-post as membranous layer of subcut tissue of perineum

Arterial Supply

Artery	*Origin*
Post Scrotal branch of perineal	Internal pudendal
Ant scrotal branch of deep ext pudendal	Femoral
Cremasteric	Inferior epigastric

Innervation

Nerve	Origin	Dist
Genital branch of Genitofemoral	L1,2 plexus	Anterolateral surface
Ant Scrotal	Illioinguinal (L1)	Anterior surface
Post Scrotal	Perineal branch of Pudendal (S2-4)	Posterior surface
Perineal branch	of post cut nerve of thigh (S2-4)	Posteroinferior surface

TESTIS

Fascia

- *Tunica vaginalis*: visceral & parietal
- *Tunica Albuginea*: fibrous testicular coat

Testes

- Seminiferous tubules → straight tubules → rete testis → efferent ducts

Testicular Artery

- Branch of Ao inf to renal
- Retroperitoneal
- Crosses ant to ureters
- Deep ring → ing canal → superficial ring → spermatic cord (ant to ductus)

Venous

- Pampiniform Plexus → *testicular vein (R → IVC, L → Renal)*
- Surrounds testicular artery

Lymphatics: Scrotum vs Testes

- Scrotum → lumbar nodes
- Testes → superficial inguinal nodes

INGUINAL HERNIAS

Characteristic	Direct (Acquired)	Indirect (congenital)
Risk Factors	Weakness in wall ∴ Older	Patency of processus vaginalis ∴ Younger age group
Frequency	25% of inguinal hernias	75% of inguinal hernias
Cavity Exit	Peritoneum & transversalis fascia	Peritoneum & all layers of wall
Course	Medial to inferior epigastric vessels Enters canal in medial 1/3	Lateral to inferior epigastric vessels Travels full length of canal
Wall Exit	Superficial ring, lateral to cord, not into scrotum	Superficial ring, within cord, within scrotum

ABDOMEN

❒ PERITONEUM & CAVITY

Peritoneum
- *Parietal:* innervated by same nerves as overlying skin region – localises well (except diaph)
- *Visceral:* innervated by same nerve as organ involved – poorly localises pain (to dermatomes)

Peritoneal Cavity
- Closed in males
- Exposed in females via uterine tubes

Relationship to viscera
- Intraperitoneal = *completely* invaginated by visceral peritoneum
- Retroperitoneal = *incompletely* invaginated
- Secondary retroperitoneal = forced into incomplete invagination through development
  eg desc/asc colon, most of duodenum, pancreas)

PERITONEAL FORMATIONS

Mesentery
- Double layer of peritoneum containing neurovascular communication to organ

Omentum
- Double layered extension from *stomach* & *proximal duodenum* over inferior viscera

Greater Omentum		Lesser Omentum
four layers since it folds back upwards > curvature of stomach/prox duodenum → ant transverse colon	VS	2 layers < curvature of stomach/duodenum → liver

Ligaments
- Double layered peritoneum connecting an organ to either another organ or wall

Liver	• Falciform → abdo wall • Hepatogastric (membranous part of lesser omentum) • Hepatoduodenal (thickened edge of lesser omentum, contains portal triad)
Stomach	• Gastrophrenic • Gastrosplenic • Gastrocolic (aka > *omentum*)

SUBDIVISIONS
Greater Sac
- Outside of greater/lesser omentum/transverse mesocolon
- *Supracolic* = ant to > omentum
- *Infracolic* = post to > omentum
  - Right & left infracolic spaces (separated by mesentery of small intestines)
  - Paracolic gutters allow R & L communication

Lesser Sac (omental bursa)
- Within greater/lesser omentum/transverse mesocolon
- Superior & inferior recess

Omental Foramen
- Communication btwn > and < sacs
- Post to free edge (right) of < omentum

Borders

Ant	Hepatoduodenal ligament (containing portal triad)
Post	IVC, R crus diaphragm
Sup	Liver
Inf	1st part duodenum

❒ ABDOMINAL VISCERA

Oesophagus
- Finishes at *T11/7th* left costal to enter stomach
- Outer long/inner circ muscle
- Ant surface covered by > omental peritoneum vs post by < omental peritoneum
- Arterial supply: *L gastric* (from celiac trunk) and *L inf phrenic*
- Venous: *Submucosal → left gastric → portal*
  OR *Oesophageal → azygous → venous angle*
- Lymphatics: left gastric → celiac
- Innervation: oesophageal plexus (vagus), greater splanchnic nerves

Constrictions
- ***Cervical*** due to UOS (made of cricopharyngeus muscles
- ***Thoracic*** due to Ao, L main bronchus
- ***Diaphragmatic*** due to oesophageal hiatus of right crus @ **T10**

STOMACH

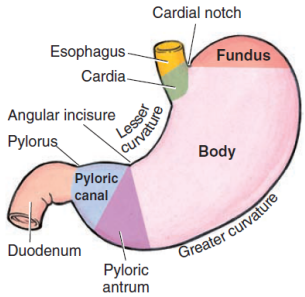

Part	Level
Cardia	6th cartilage, T11
Fundus	6th rib MCL
Pylorus	8th cartilage/L1†
> Curve	5th IC space L MCL → 9-10th cartilage

†Transpyloric plane (1/2 way btwn pubic symphysis & manubrium)

Venous

Lesser Curve	L & R gastric veins → Portal Short gastric vein → splenic + SMV → Portal Prepyloric vein near entry of R G vein
Greater Curve	R gastro-omental → SMV L gastro-omental → splenic vein + SMV → Portal → SMA Pancreaticoduodenal vein → SMA near entry of R GO vein Middle gastric → splenic

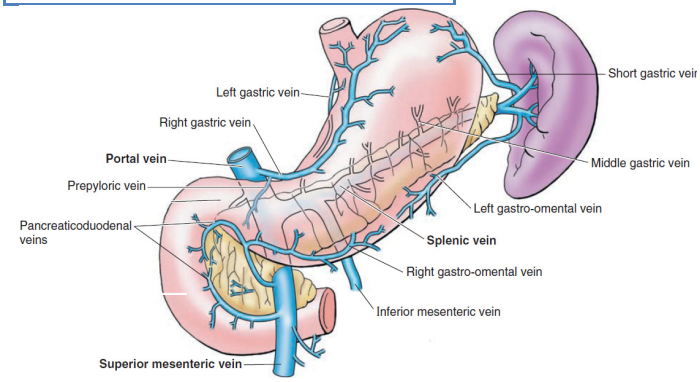

Lymphatics

Region	1st order Drainage	2nd order drainage
Superior 2/3	Gastric nodes	Celiac nodes
Fundus & Sup Body	Pancreaticosplenic nodes	
Inferior R 2/3	Pyloric nodes	
Inferior L 1/3	Pancreaticoduodenal nodes	

Innervation
Vagus

Anterior (from left vagus)
- Ant to oesophagus
- *Hepatic* & *duodenal branches* as it descends on < curve & exits in hepatoduodenal ligament
- Rest cont along < curve as *ant gastric branches*

Posterior (from right vagus)
- Post to oesophagus
- Supplies ant/post stomach
- Celiac branch → plexus
- Posterior gastric branch

Arterial Supply to FOREGUT

Artery	Origin	Course
Celiac Trunk	Abdo Ao	Short Dist: foregut + prox duodenum
Left Gastric	Celiac	Ascends to oesophageal hiatus Descends along < curve | ⇔ r gastric Dist: distal oesophagus, < curve
Splenic		Sup border of pancreas → splenorenal ligament → hilum spleen Dist: Pancreas (body), spleen, > curve, post body
Hepatic		Hepatoduodenal ligament Dist: everything but oesophagus
Posterior Gastric	Splenic	Ascends post wall of < sac Dist: post wall/fundus of stomach
Left Gastro-Omental		> Curve ⇔ Right Dist: > curve
Short Gastric		→ Fundus Dist: Fundus
Gastroduodenal	Common hepatic	Post to pylorus → branches Dist: stomach, pan, prox duodenum & bile duct
Right Gastric		< curve Dist: < curve ⇔ left
Cystic	R hepatic	In hepatoduodenal ligament Dist: gallbladder, duct
Right Gastro-omental	Gastroduodenal	> curve ⇔ left Dist: > curve
Sup Pancreaticoduodenal		Desc ant/post to pancreatic head Dist: Sup head of pancreas, prox duodenum
Inf Pancreaticoduodenal	SMA	Asc ant/post to pancreatic head Dist: Inf head of pancreas, distal dudoenum

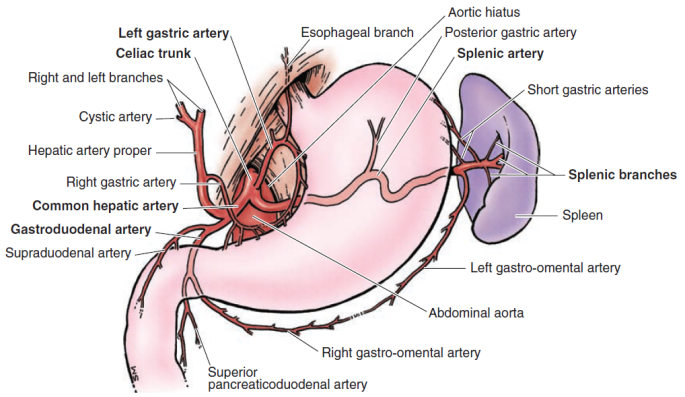

ABDOMEN

Small Intestines

Duodenum

- Ends at duodenojejenal flexure @ L2

Part	Ant	Post	Med	Sup	Inf	Level
Superior	Peritoneum, gallbladder Quad lobe	Bile duct GD a. Portal/IVC	Pylorus	Neck of gallbladder	Neck of pancreas	L1
Descending	Tran colon + meso Coils of SI	R kidney + hilar Psoas Major	Head pan + duct Bile duct	Part 1	Part 3	L2-3
Inferior	SMA/SMV Coils of SI	Psoas major IVC/Ao R ureter		Head pancreas SMA/SMV	Ilium	L3
Ascending	Mesentery Jejunum	Psoas major Ao	SMA/SMV Head pan	Body Pan	Coils jej	L3

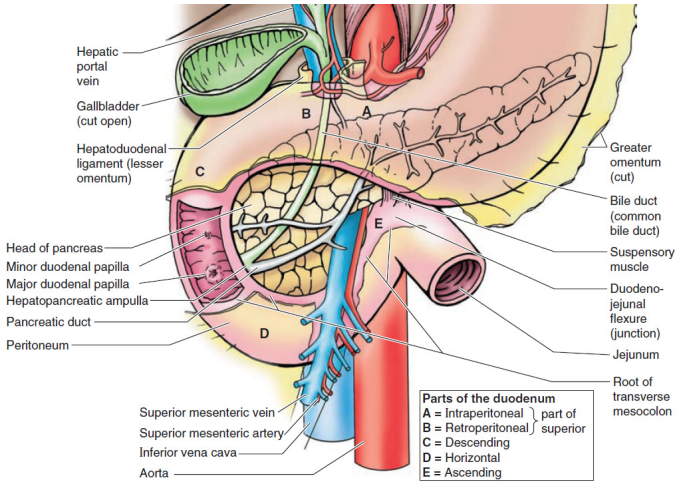

Arteries

- Celiac trunk proximal to ampulla (via *GD a.* & *Sup PD a.*)
- SMA via *Inf PD a.*

Lymphatics

- Anterior → *PD nodes* → pyloric nodes
- Posterior → *SMA nodes*

Jejunum & Ilium

Characteristic	Jejunum	Ilium
Colour	Deep red	Pale pink
Calibre	2-4cm	2-3cm
Wall	Thick/heavy	Thin/light
Vascularity	Greater	Lesser
Vasa recta	Long	Short
Arcades	Less Loops	More Loops
Fat in Mesentery	Less	More
Circular folds	Large, Tall, Packed	Low & Sparse
Peyers patches	Few	Many

Vascular

- *SMA → jejenul & ileal arteries → arcade → vasa recta*
- *SMV + splenic vein (join behind head of pancreas) → portal vein*

Lymphatics

- Juxta-intestinal nodes (in wall) → mesenteric → *Superior central* (on SMA)
- Terminal ileum → iliocolic nodes

Innervation

Proximal to left flexure

- Sympathetic: T8-10 form superior *mesenteric plexus* on SMA
- Parasympathetic: *Posterior vagal trunks*

Distal to left flexure

- Sympathetic: *lumbar splanchnic n.*
- Parasympathetic: *pelvic splanchnic n.*

LARGE INTESTINES

Caecum

- No mesentery
- Iliocolic artery (SMA)

Appendix

- Mesoappendix from ileal mesentery
- 64% retrocaecal
- Appendicular artery (branch of iliocolic)

Both

Lymphatics

→ Iliocolic nodes → sup mesenteric

Innervation

Superior mesenteric plexus

Colon

Ascending	•	Ends at R hepatic flexure (9-10th ribs)
Transverse	•	L hepatic flexure attached to diaphragm via phrenicocolic ligament
	•	Mesocolon inf border pancreas
Descending	•	Desc colon has short mesentery ∴ unlikely volvulus
Sigmoid	•	Rectosigmoid jcn @ S3
	•	Long mesentery – upside down V with vessel bifurcation as apex

Arteries

SMA	proximal to left flexure	R colic & iliocolic a.	Asc Colon
		Middle > Right = Left colic	Transverse
IMA	distal to left flexure	Left colic	Desc & Sigmoid
		Inf mesenteric	
		Sigmoid	

- All branches anastomose near colon wall to become *marginal arteries*

SPLEEN

Inferior	L colic flexure
Anterior	*left 9th-11th ribs*[1], stomach (*gastrosplenic ligament*)
Lateral	L kidney (*splenorenal ligament*)
Medial	Tail of pancreas (together form boundary of < sac)

Atrial from splenic a. (branch of celiac) travel on ant surface of pancreas (behind < sac)

[1]Long axis parallel with 10th rib

PANCREAS

- L1, 2
- Head, neck , body, tail (head attached to 2nd part duodenum)
- Uncinate process ant to SMA/Neck post to pylorus

Arterial supply

- Head: *Sup & Inf PD a.*
- Neck, body tail: splenic, GD a., SMA directly

LIVER

- Deep to ribs 7-11 on r and towards left nipple
- *Hepatorenal recess* is gravity dependant from omental bursa
- Portal triad: bile duct, hepatic artery, portal vein
- 4 lobes | 8 segments (indep blood supply)
  - Segments start on left sup part and numbered clockwise (NB seg I is **caudate lobe** on post aspect of liver)

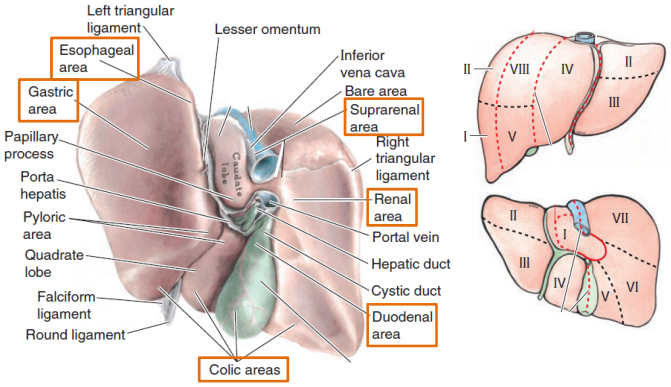

Bloods Supply

- Dual
- *Portal vein* has 40% more O_2 than other veins → *parenchyma*
- *Hepatic artery* → *non-parenchyma* eg ducts

Lymphatics

- Supplies 25-50% of lymph to thoracic duct
- Ant surface & deep vessels → hepatic nodes → celiac → *cistern chyli*
- Post surface → phrenic nodes → post mediastinal nodes

Bile Ducts & Gallbladder

- R & L hepatic duct → common hepatic duct → joins cystic duct → bile duct
- Bile duct forms at the free edge of lesser omentum
- Lies on post groove on head of pancreas post
- Arterial supply: prox (*cystic*), middle (*r hepatic*), post (*sup PD a. & GD a.*)

Gall bladder

- Post to liver | Ant to duodenum
- Holds 50ml
- Fundus (9th cartilage MCL), body, neck
- Arterial: cystic a. (branch of r hepatic a. in "*cystohepatic triangle*" ie common hepatic/cystic duct/inf edge liver)
- Venous drainage: fundus/body → sinusoids

Portal-Systemic Anastomoses

- Inferior oesophagus
- Anal canal
- Paraumbilical
- Bare areas of secondarily retroperitoneal organs (colon, liver)

ABDOMEN

KIDNEYS, URETERS, SUPRARENALS

- Perinephric fat → into renal hilum
- Paranephric fat without the capsule (ass with lumbar region)
- *Primary attachment with diaphragm* (renal fascia cont sup as diaphragmatic fascia)

KIDNEYS

- T12-L3 / Deep to 11th & 12th ribs
- NB Inf pole RIGHT kidney a fingers breadth above iliac crest

  Hilum
  - L kidney just above Transpyloric plane 5cm from median
  - R kidney transects Transpyloric plane
  - Contents (ant to post)t: vein, artery, duct
- Renal papilla → minor calyx → major calyx → renal pelvis → ureter
- ***Psoas major muscle*** posterior ∴flexion of hip with pyelonephritis → pain

Ureters

- Pass over pelvic brim @ bifurcation of iliac arteries
- Run along the lateral wall and insert inf border of bladder
- Surface anatomy: 5cm lat to L1 → PSIS
- 3 constrictions: entry/pelvic brim/exit

Suprarenal Glands

- Retroperitoneal
- Major attachment is crura of diaphragm (not kidney)
- Hilum for ***vein and lymphatics*** (arteries and nerves enter at multiple sites)
- ***Intra-suprarenal space*** (right to left): IVC, R crus, coeliac ganglion, celiac trunk, SMA, L crus

Right gland
- Pyramidal
- Sits higher
- Anterolateral to r crus
- IVC contacts antero medially
- Liver anterolaterally

Left gland
- Crescent shaped
- Sits medial on superior surface
- Associated with spleen, stomach, pancreas, left crus

Vasculature

Kidneys
- Branch of Ao @ L1/2
- Since Ao on left, R is longer, passes post to IVC to reach kidey
- Branch into 5 segmental arteries either side
- S/AS/AI/I (all from anterior branch)
- Posterior branch
- NB some extra renal arteries can enter – via poles

Ureters
- Mainly from renal a. with variable contribution directly from Ao, iliacs, testicular/ovarian a.

Suprarenal
- Suprarenal a.: superior = inferior phrenic - most
  Middle = Ao
  Inferior = renal a.

Veins

Kidneys
- L & R renal veins → IVC
- L is longer and receives from *gonadal* and communicates with *lumbar* and *suprarenal*
- NB L renal vein returns to IVC under SMA as it branches from Ao ∴ traction on SMA → occlusion

Ureter
- Renal & gonadal veins

Suprarenal
- R → IVC, L + inf phrenic → renal v.

Lymphatics

- Lumbar nodes
- Mid ureter → common iliac
- Inf ureter → common/ext/int iliac

Innervation

- Renal nerve plexus derives from splanchnic nerve (mostly inferior)
- Ureter supply from: renal, abdominal Ao, sup hypogastric plexus
- Pain → T11/L2
- Suprarenal: coeliac plexus with some from splanchnic T10 to L1

❒ OVERVIEW OF ABDOMINAL INNERVATION

SYMPATHETICS

Synapsing
- Cell bodies in IML
- Fibres exit as ant root → ant rami → white comm rami → *sympth trunk (paravert ganglia)*
- NB all plexuses are shared with parasympth and afferent

Distant Synapsing: ***Abdominopelvic Splanchnic***
- Presynaptic fibres → abdo cavity
- IML (T5-L2/3) → ant root → ant rami → white comm branches → sympth trunks paravert ganglia (WITHOUT synapsing) → splanchnic nerves → *Prevertebral ganglia* → periarterial plexus → viscera

Splanchnic N	*Level*	*Prevertebral Ganglia*	*Organ*
Cardiopulmonary	C4-T5	Cardiac Pulmonary Oesophageal	Heart Lungs Oesophagus
Greater	T5-9	Celiac	liver, gallbladder, stomach, pancreas, spleen
Lesser	T10	Aorticorenal	Kidney[1]
Least	T11		
Lumbar	L1-2	Sup Mesenteric Inf Mesenteric	Intestines Bladder Genitilia

[1] Suprarenal has postsynaptic body within viscera (doesn't synapse in coeliac ganglion)

Visceral Sensory

- With sympathetic fibres
- sensory for reflex is via parasympathetic tracts

Foregut	T6-9
Midgut	T10-12
Hindgut	T12-L2
Sigmoid	S2-4

PARASYMPATHETIC

Anterior/posterior vagal trunks (CN III, VII, IX in face)
- Cont of L & R vagal nerves from oesophageal plexus and traverse ***oesph hiatus***
- Convey presynaptic parasympathetic as well as afferent ass with reflexes
- Innervate to ***left colonic flexure***

Pelvic splanchnic nerves
- Direct from S2-4
- Presynaptic fibres to inf hypogastric plexus

- Abdominal autonomic plexus → Intrinsic parasympathetic ganglia
- nerve plexus are mixed with sympathetic and visceral afferent fibres
- presynaptic fibres terminate in intrinsic ganglia

Autonomic Plexus
- celiac, sup, inf mesenteric – all along Ao
- intrinsic ganglia (prevertebral) exist within walls of viscera
- Sup mesenteric has median/lat (x2) roots (median → celiac plexus, lateral → lesser, least splanchnic)
- inferior mesenteric plexus near IMA

  Intermesenteric plexus (btwn SMA/IMA)
  - Gives rise to renal, testicular/ovarian, ureteric plexus

Superior hypogastric plexus
- Cont of Intermesenteric and inf mesenteric plexus
- Sits ant to Ao @ bifurcation→ Ureteric & testicular plexus

ABDOMEN

DIAPHRAGM

- Radial muscle peripherally converging from 3 directions into a ***central tendon*** (aponeurosis)

3 parts

Sternal	Not always present
Costal	Forms domes, attaches to inferior 6 cartilages
Lumbar	Diaphragmatic attachments include ***crura***, medial/lateral ***arcuate ligaments, L1-3***

Crura
- Musculotendinous bands arising from L1-3 (right) or L1-2 (left)
- ***Aortic Hiatus:*** Left & Right join together as *median arcuate ligament*

Arcuate Ligaments
- Medial: cont of *psoas major* fascia from TP of L1
- Lateral: cont of *quadratus lumborum* L12 → tip of 12th rib
- Median: fusion of crura

Vessels	*Sup surface*	*Inf surface*
Arterial	Sup Phrenic (Ao) Musculophrenic & Pericardiophrenic (Int Thoracic)	Inferior Phrenic (Ao)
Venous	Musculophrenic & L Pericardiophrenic → Int Thoracic R Pericardiophrenic → IVC	Inf phrenic R → IVC L → IVC & Suprarenal
Lymphatics	Diaphragmatic nodes → phrenic → parasternal & posterior mediastinal	Superior lumbar node
Innervation	Motor: C3-5 via phrenic Sensory: central = phrenic, peripherally = IC/subcostal (T5-11/T12)	

NB sup/inf surface have freely communicating lymphatics

Diaphragmatic Apertures

Aperture	*Content*	*Boundaries*
Caval	IVC R Phrenic (terminal branches) Lymphatics from liver → middle phrenic/mediastinal nodes	Within central tendon R of median T8/9 disc
Oesophageal	Oesophagus Ant/Post vagal trunks Left gastric a. (oesophageal branch) Lymphatics	R crus T10
Aortic	Aorta Thoracic duct +/- hemi/azygous	Post to median arcuate T12

Diaphragmatic Apertures: Smaller Openings

Aperture	*Content*
Sternocostal triangle	Btwn sternal/costal attachment of diaphragm Transmit lymphatic vessels & sup epigastric vessels
Medial Arcuate Ligament	Sympth trunk & least splanchnic nerve run deep
Crus	Greater and lesser splanchnic nerves (separately)
Gaps for Psoas Major	Psoas Major

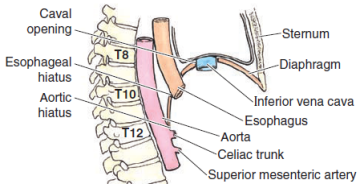

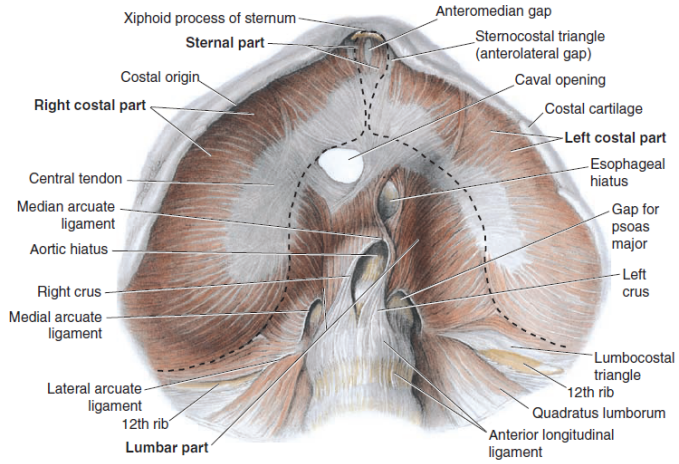

POSTERIOR ABDOMINAL WALL

- L1-5
- Diaphragm
- Fascia
- Lumbar plexus
- Muscles: *psoas, quadratus lumborum, Iliacus, transversus abdo, oblique muscles*

Fascia

Endoabdominal fascia
- Btwn parietal peritoneum & musc
- Cont with ***transversalis fascia*** posteriorly

Psoas fascia
- Covers psoas major, lumbar vert/pelvic brim
- Superiorly → thickened as medial arcuate ligament
- Laterally → quadratus lumborum & thoracolumbar fascia
- Inferiorly → iliac fascia (over Iliacus)

Thoracolumbar Fascia

3 layers + investing muscle

Posterior & middle	Enclose vertical deep back muscles ▪ Stronger than rectus sheath because it attaches to TP ▪ Attaches laterally with *internal oblique* and *transversus abdominus* (ie same attachments as rectus sheath except lat dorsi instead of ext oblique) ▪ Inferiorly 12th rib → iliac crest
Anterior	Encloses *quadratus lumborum* • TP/iliac crest/12th rib (ie same as muscle attachment) • Thickens superiorly to form ***lateral arcuate ligament***

Muscles

Psoas Major	TP L-spine Lateral bodies T12-L5	Tendon to lesser trochanter[1]	L1-3	Flex thigh[2] Flex vert laterally Flex trunk (eg siting) Houses lumbar plexus
Iliacus	Sup 2/3 Iliac fossa, ala of sacrum, ant SI ligament	Lesser trochanter & shaft + Psoas tendon	L2-4	Flex thigh[2] Stabilise hip
Quadratus Lumborum	TP L-spine Medial ½ inf border 12th rib	Iliolumbar ligament & internal lip of iliac crest[3]	T12-L4	Extend/lat flex vert Fixes 12th rib during insp

[1]inferior to inguinal ligament | [2]Chief
[3]Subcostal nerve passes post to lateral arcuate ligament on surface of quadratus

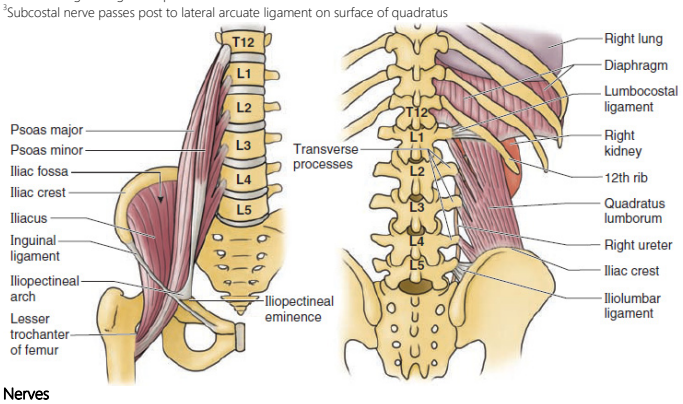

Nerves

- *Subcostal nerve*: enter abdo lateral to lateral arcuate ligament past transversus abdominus & int oblique to supply ***ext oblique & skin***
- *Lumbar Spinal Nerves*
  - Post rami → back muscles & skin vs Ant rami does rest
  - L1-2 gives rise to ***lumbar splanchnic nerve*** → SM or IM ganglion → sympathetic
  - Four lumbar sympathetic ganglia sit btwn vertebrae & psoas major

Lumbar plexus

L1-4 ant rami

Major Branches

Femoral	L2-4, Iliacus, flexors of hip, extensors of knee, lateral to psoas major
Obturator	L2-4, emerges med to psoas maj → lesser pelvis → obt foramen → med thigh → adductor musc
Lumbosacral	L4,5, over ala of sacrum → sacral plexus (S1-4 ant rami)

Minor Branches

Illioinguinal & Illiohypogastric	L1, post to medial arcuate ligament, ant to *Obturator lumborum* → superior/parallel to iliac crest → *transversus abdominus*→ *int/ext obliques* → *inguinal/pubic abdomen*
Genitofemoral	L1, 2 pierces *psoas major* → lateral to iliac a. → branches into femoral & genital
Lat cutaneous	deep to inguinal ligament, medial to ASIS → lateral skin thigh

ABDOMEN

Vessels

Aorta

- Subcostal a. from thoracic part but supplies some abdominal content
- T12 → L4 (divide into left/right common iliac) → follow medial border psoas major → Internal/external iliacs
  - Internal → pelvis
  - Ext → follows Iliopsoas → deep inguinal ring (gives off inf epigastric & deep Cx ring before exiting)

Plane	*Class*	*Dist*	*Branch*	*Level*
Ant midline (1)	Unpaired visceral	Digestive tract	*Celiac* *Sup mesenteric* *Inf mesenteric*	T12 L1 L3
Lateral (2)	Paired visceral	Urogenital & Endocrine	*Suprarenal* *Renal* *Gonadal*	L1 L1 L2
Posterolateral (3)	Paired parietal	Diaphragm, body wall	*Subcostal* *Inf phrenic* *Lumbar*	L2 Tqw L1-4

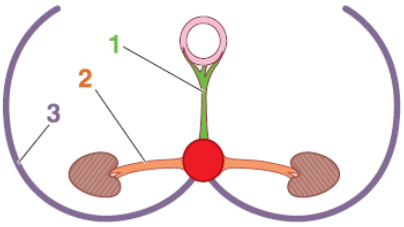

Three vascular planes

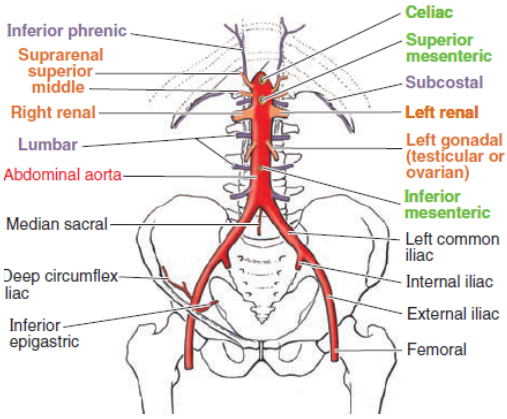

Veins

- Go to IVC via *portal-hepatic system*
- Paired veins follow paired arteries in IVC
  - Inferior phrenic, L3 & L4 lumbar veins
  - Common iliac veins
- Unpaired veins follow hepatic-portal course directly
- L gonadal vein → direct into IVC

Lymphatics

- Common iliac nodes → R & L lumbar nodes
- GIT → preaortic nodes (inf/sup mesenteric nodes)
- Inferior end of thoracic duct is expanded as *cisterna chyli* @ L1,2 btwn r crus and Ao
  - Goes through *Ao hiatus*
  - Enters left venous angle