LOWER LIMB

❒ DEVELOPMENT

- L2-S2 buds form (1 week behind upper limb)
- Distal ends flatten with palmar and sole directed anteriorly
- Elbows & Knees elongate laterally = palms and soles rotate medially
- At 7th week UL rotates caudally, LL rotates cranially
- Counter clockwise rotation of LL → 1st digit medial

❒ BONES

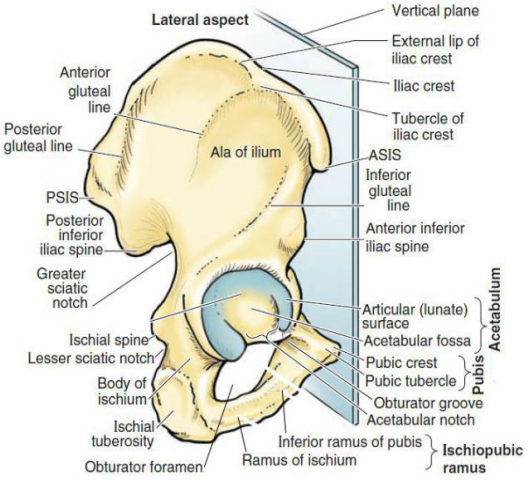

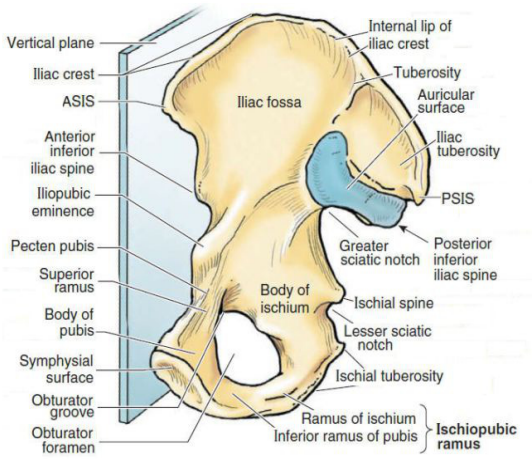

HIP BONE

- Ilium, Ischium & Pubis
- Acetabulum displays them joining as triradiated cartilage

Ilium

Iliac crest
- Joins ***ASIS*** to ***PSIS***
- PSIS forms sup border of ***sciatic notch***
- Tubercle of ***iliac crest*** occurs 1/3 from ASIS (marks widest point of crest)

Ala
- Lateral surface has post/ant/inf gluteal lines (representing gluteal attachment)
- Medial surface ***has iliac fossa*** (for iliac muscle attachments), ***auricular surface***, ***iliac tuberosity***

Ischium
- ***Ischiopubic ramus*** (ischial ramus + inferior public ramus) = inf boundary of ***obt foreman***
- ***Ischial tuberosity*** (separates greater from ***lesser sciatic notch***) – tendons of post thigh

Pubis
- Body, Superior & Inferior Ramus
- ***Pubic crest*** (symphyseal surfaces of 2 pubii, abdominal muscles attach)
- ***Pubic tubercle*** – lateral edge of pubic crest, ***inguinal ligament*** attaches
- Medial thigh muscle attachments

Obturator Foramen
- Contains Obturator ***canal*** and ***membrane***
- Canal: Obturator nerve & vessels
- Membrane: muscle attachments

Acetabulum
- ***Lunate surface*** = articular surface
- ***Acetabular notch***: inferior disruption in border
- ***Acetabular fossa***: non articulating depression superior to notch

FEMUR

Proximal
- Head (contains ***fovea*** for ligament of the head)
- Neck
  - ***Greater Trochanter***: postosuperior, abductors and rotators
  - ***Lesser Trochanter***: posteromedial, flexor attachment
  - ***Intertrochanteric*** line – joins trochanters anteriorly
  - ***Intertrochanteric crest*** – joins trochanters posteriorly (has ***quadrate tubercle***)
  - ***Trochanteric fossa***: superiomedial to greater trochanter

Shaft
- ***Linea aspera***: longitudinal line for adductor muscles
  - Medial cont sup as spiral line → anterior surface as ***intertrochanteric line***
  - Lateral cont sup to ***gluteal tuberosity***
  - Mid central shaft cont inf → ***supracondylar lines***

Distal
- ***Condyles***: join ant as patella surface, separate infer/post by ***intercondylar fossa***
- ***Epicondyles***: collateral ligament attachment (medial also has ***adductor tubercle***)

TIBIA

Proximal
- ***Condyles***: Medial & Lateral
- ***Articular surface***: intercondylar eminence (made of med & lat intercondylar tubercles)
- ***Anterolateral tibial tubercle***: distal attachment of thigh fascia
- ***Fibular articular facet***

Shaft
- ***Tibial tuberosity***: anterior, patella ligament insertion
- ***Soleal line***: posterior, for Soleal muscle attachment

Distal
- ***Medial malleolus*** & ***fibular notch***

FIBULA
- Non weight bearing
- Distal attachment for 1 muscle, origin for 8 others
- Held to fibula by ***tibiofibular syndesmosis*** (incl Interosseous membrane)

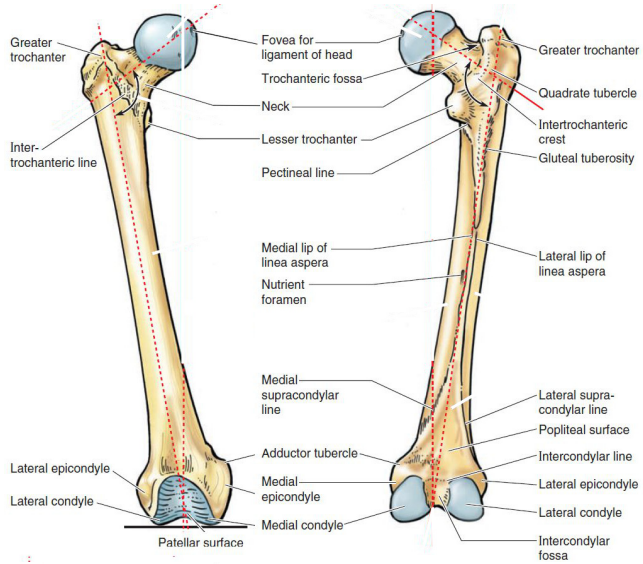

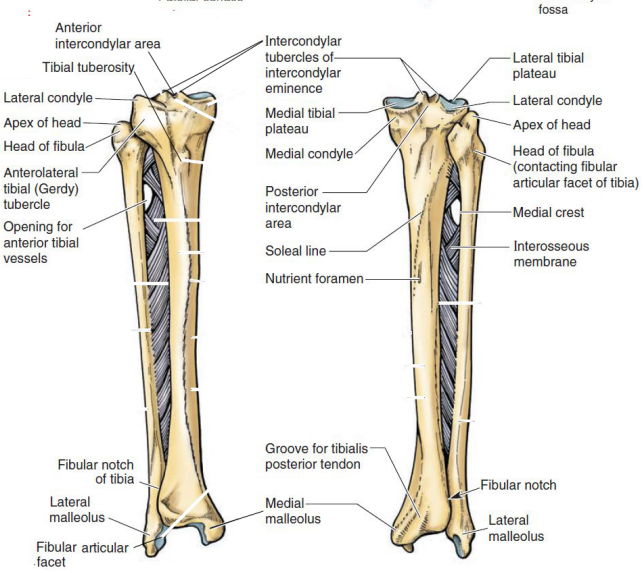

LOWER LIMB

❒ BONES

FOOT

Tarsus (hind foot)

Talus
- ***trochlea*** (art surface***), body, neck, head***
- no muscular or Tendinous attachments
- Body: posteriorly has a groove for flex halluces longus btwn medial & lateral tubercles

Calcaneus
- ***Fibular trochlea***: lateral, anchors everters of foot
- ***Sustentaculum tali***: medial projection to increase contact with talus
- ***Calcaneal tuberosity***: medial, lateral, anterior

Cuboid
- ***Tuberosity of cuboid*** on inferior lateral surface
- Laterally has groove for tendon of fibularis longus

Navicular
- ***Navicular tuberosity*** medially to attach arch of foot ligaments
- Prox: talus | distal: 3 cuneiforms

Cuneiforms (1-3)
- Medial = 1 | Intermediate = 2 | Lateral = 3

Metatarsals & Phalanges
- Articulate with cuboid and cuneiforms
- 5th MT has ***tuberosity*** over cuboid laterally
- 1st MT has sesamoid bones on plantar surface
- Phalanges like upper limb

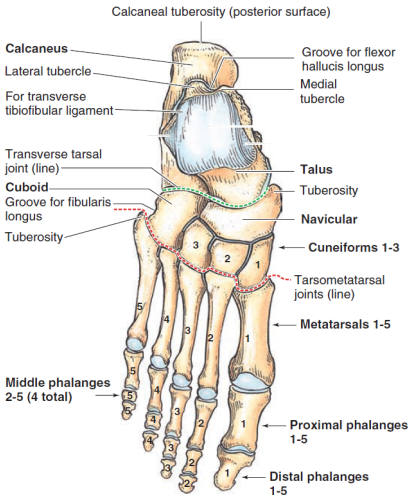

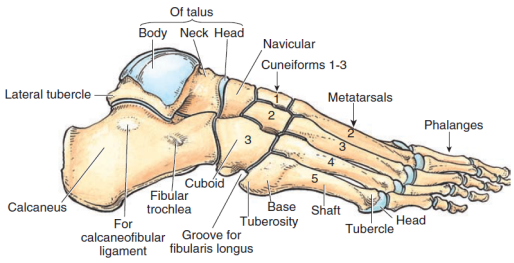

❒ FASCIA, VEINS, LYMPHATICS, NERVES

FASCIA

Fascia Lata (deep fascia of thigh)
- ***Iliotibial tract***: lateral thickening of fascia lata, originates at iliac tubercle

Superior structures
- Inguinal ligament, pubic arch, body of pubis, pubic tubercle
- Scarpa fascia (abdominal fascia)
- Iliac crest
- Sacrum, coccyx, sacrotuberous ligament, ischial tuberosity/Ischiopubic ramus

Inferior structures
- Bone around knee
- Dee fascia of leg

Compartment	Action	Innervation
Anterior	Extensor	Femoral
Medial	Adductor	Obturator
Posterior	Flexor	Tibial branch of sciatic

  - ***Lateral intermuscular septum strongest*** – others not mentioned
    - Iliotibial tract → linea aspera (on femoral shaft) + lat supracondylar line

Saphenous opening:
- inf to medial inguinal ligament
- medial border smooth, other borders thickened as ***falciform margin***
- overlaid with ***cribriform fascia***
- great saphenous vein & lymphatics runs through (to femoral vein)

Crural Fascia (deep fascia of leg)
- thick proximally then thins out distally apart from extensor retinacula over ant/sup ankle

Compartments
- Walls: ***ant/post intermuscular seta, Interosseous membrane***
- Anterior (dorsiflexion)
- Lateral (fibular)
- Posterior (plantarflexion) – ***transverse intermuscular septum*** sep superficial from deep

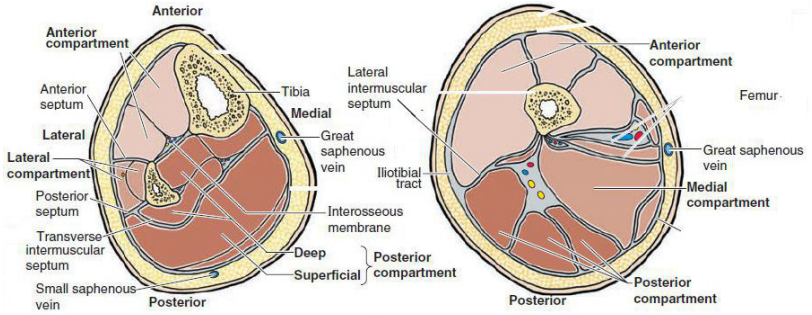

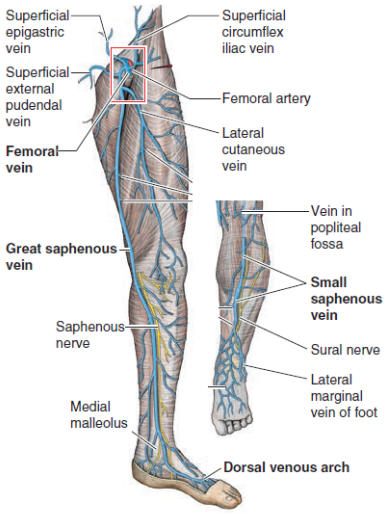

Anteroinferiorly: forms ***superior & inferior retinaculum***
- Sup: strong, tib to fib prox to malleoli
- Inf: medial malleoli → anterosuperior calcaneus

VEINS

Superficial

Great saphenous
- Dorsal vein of great toe + dorsal venous arch of foot
- Anterior to medial malleolus
- Post to medial condyle of femur
- Anastomoses with small venous (either via tributaries or ***accessory saphenous***)
- Empties in femoral vein after passing deep via saphenous opening of fascia lata
- ***Lateral and anterior cutaneous*** veins empty near saphenous opening

Small saphenous
- Dorsal vein of little toe + dorsal venous arch
- Posterior to lateral malleolus (as lateral marginal veins of foot)
- Ascends towards midline ½ way up lower leg
- Travels deep btwn heads of gastrocnemius
- Empties into popliteal vein

Deep

Lower Leg
- Anterior: dorsal venous arch → ***anterior tibial vein*** → popliteal
- Posterior: ***medial/lateral plantar*** → post to malleolus → ***posterior tibial and fibular veins***

Above Lower Leg
- Knee: ***popliteal vein***
- Thigh: ***femoral vein***

❒ FASCIA, VEINS, LYMPHATICS, NERVES

LYMPHATICS

Superficial

- Run with great saphenous → empty to ***superficial inguinal*** → ***external iliac nodes*** OR
- Run with small saphenous → ***popliteal nodes*** → deep inguinal nodes (medial to fem artery)

Iliac nodes (ext/common) → ***lumbar lymphatic trunks***
NB Deep lymphatic drainage same as when small saphenous goes deep

CUTANEOUS NERVES

Thigh

Subcostal	T12 → Inf border 12th rib → lateral branch over iliac crest Distribution: skin inf to ant iliac crest and greater trochanter
Illiohypogastric	L1 → lat & ant cutaneous branches on iliac crest Distribution: superolateral quadrant of buttocks
Illioinguinal	L1 → through inguinal canal → branches into femoral and scrotal/labial Dist: Medial Femoral triangle
Genitofemoral	L1-2 → over psoas major → branches into genital and femoral Dist: Lateral Femoral triangle & ant genitalia
Lateral Cutaneous	L2-3 → deep to inguinal ligament Dist: ant/lat thigh
Ant Cutaneous	L2-4 → arises in femoral triangle Dist: ant/medial thigh
Cut branch of Obturator	L2-4 → btwn adductor longus & brevis Dist: middle medial thigh
Post Cutaneous	S1-3 → greater sciatic foramen → deep to fascia lata Dist: Majority of post thigh

Leg/Foot

Saphenous	L3-4 (femoral nerve)→ crosses (not into) adductor hiatus → medial knee (deep to Sartorius) Dist: medial leg and foot
Superficial fibular	L4-S1 → lateral compartment of leg → deep fascia Dist: anterolateral leg, dorsum foot (not webbing of 1st/2nd toes)
Deep fibular	L5 → 1st, 2nd MT Webbing of 1st/2nd toes
Sural	S1-2 (tibial nerve) Dist: Posterolateral leg, lateral foot
Medial plantar	L4-5 Dist: medial sole & medial 3 ½ toes
Lateral plantar	S1-2 Dist: lateral sole & lateral 1 ½ toes
Calcaneal	S2-1 (tibial/Sural nerves) Dist: Heel
Superior clunial	L1-3 rami Dist: sup/central buttocks
Medial clunial	S1-3 → sacral foramina → cutaneous Dist: medial buttocks, intergluteal cleft
Inferior clunial	S2-3 (post cut) → deep to glut max Dist: inf buttocks

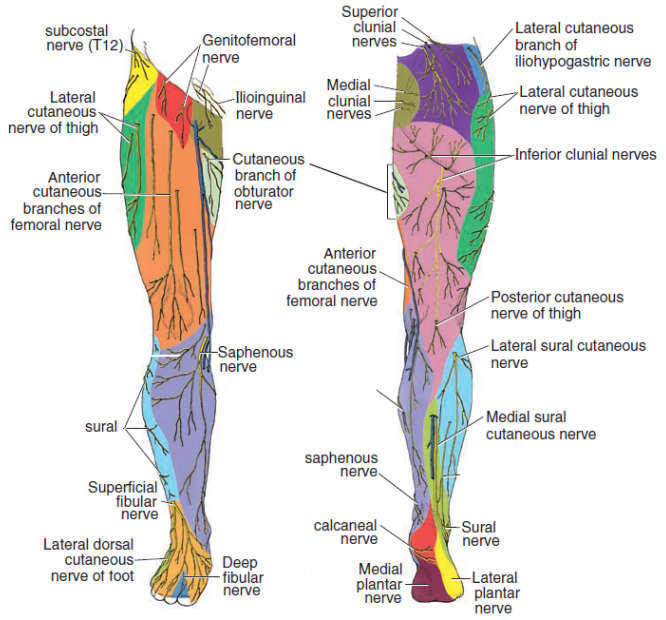

Myotomes

Action	Spinal Root
Thigh	
Lateral rotation	L5,S1
Medial rotation	L1,2,3
Flexion	L2,3
Extension	L4,5
Abduction	L5,S1
Adduction	L1-4

Knee	
Flexion	L3,4
Extension	L5,S1

Ankle	
Plantarflexion	S1,2
Dorsiflexion	L4,5
Inversion	L4,5
Eversion	L5,S1

MTP & Phalanges	
Plantarflexion	S1,2
Dorsiflexion	L5,S1

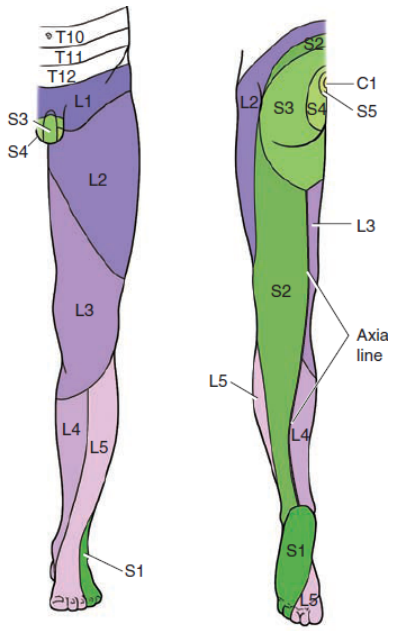

❒ POSTURE & GAIT

Standing

- Joints are most stable (largest articular surface contact)
- Centre of gravity @ anterior edge of ankle ∴ forward sway tendency

Walking

Phase	Gait	Goals	Muscles
Stance	Heel strike	Lower forefoot to ground[1]	Ankle dorsiflexors
		Decelerate	Hip extensors
		Preserve longitudinal arch foot	Intrinsic/long muscles
	Loading response	Accept weight	Knee extensors
		Decelerate	Ankle plantarflexors
		Stabilise pelvis	Hip abductors
		Preserve longitudinal arch foot	*As above*
	Midstance	Stabilise knee	*As above*
		Control dorsiflexion	Ankle plantarflexors
		Stabilise pelvis	*As above*
		Preserve longitudinal arch foot	*As above*
	Terminal stance	Accelerate mass	Ankle plantarflexors
		Stabilise pelvis	*As above*
		Preserve longitudinal arch of foot	*As above*
	Prewsing	Accelerate mass	Long flexors of digits
		Preserve longitudinal arch of foot	*As above*
		Decelerate thigh	Hip flexors
Swing	Initial	Accelerate thigh	Flexor of hip
		Clear foot	Ankle dorsiflexion
	Midswing	Clear foot	*As above*
	Terminal swing	Decelerate thigh	Knee extensors
		Decelerate leg	Knee flexors
		Position foot	Ankle dorsiflexion
		Extend knee to place	Knee extensors

[1]Uses most energy (eccentric contraction)

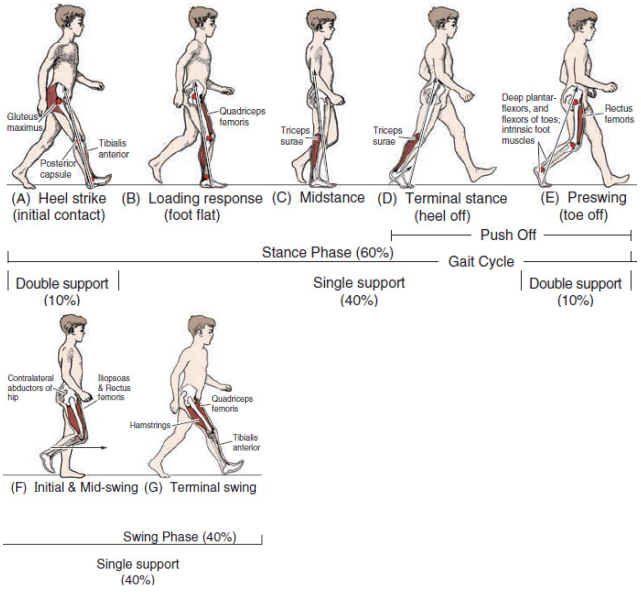

❒ ANTERIOR & MEDIAL THIGH

ANTERIOR THIGH

Flexors of hip

Pectineus	Superior Pubic Ramus	Pectineal line of femur[1]	Femoral Nerve	*Adduct*, flex, some *medial* rotation
Iliopsoas				
Psoas Major[2]	T12-L5 TP	Lesser trochanter	Ant rami of L1-3	Flex hip Stabilise joint
Iliacus	T12-L1	Iliopectineal eminence	Femoral	
Sartorius	ASIS	Superior medial tibia		*Abduct*, flex, *lateral* rotation *Flex leg, medially rotate knee*

[1]Inf to lesser trochanter

[2]*Psoas Abscess: transversalis fascia cont with psoas major fascia ∴ retroperitoneal infection → inguinal symptoms (eg TB, regional enteritis)*

Extensors of knee

Quadriceps				
Rectus femoris[1]	ASIS	Tibia: *quadriceps tendon* → base of patella → *patella ligament* → tibial tuberosity	Femoral	Extend knee
Vastus lateralis	> Trochanter Lateral lip Linea aspera			
Vastus medialis	Intertrochanteric line Medial li Linea aspera			
Vastus intermedius	Anterolateral surface femur			

NB patella is a large sesamoid bone

[1]Flexes hip

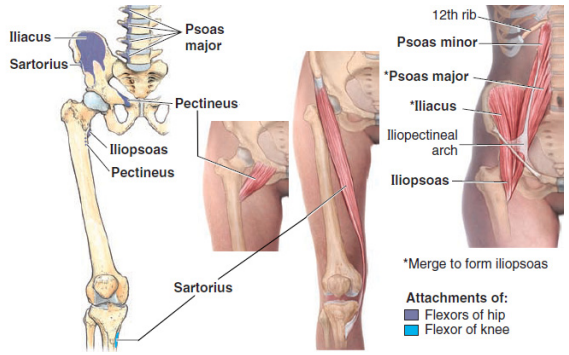

MEDIAL THIGH

Adductors of Thigh

Add Longus	Body of pubis inf → crest	Linea aspera: medial 1/3	Obturator	Adduct
Add brevis	Body, Inf ramus of pubis	Linea aspera: proximal + Pectineal line		Adduct + small flex
Add Magnus				Adduct
Adductor part[1]	Inf pubic ramus Ramus of ischium	Linea aspera, supracondylar line	Obturator	Flex thigh
Hamstring part	Ischial tuberosity	Adductor tubercle	Tibial part of sciatic	Extend thigh
Gracilis	Body, Inf pubic ramus	Proximal antero-superior tibia	Obturator	Adduct + flex leg, medial rotation
Obturator externus	Margin of Obturator foramen/membrane	Trochanteric fossa		Rotate thigh laterally

[1]adductor hiatus separates adductor from hamstring parts

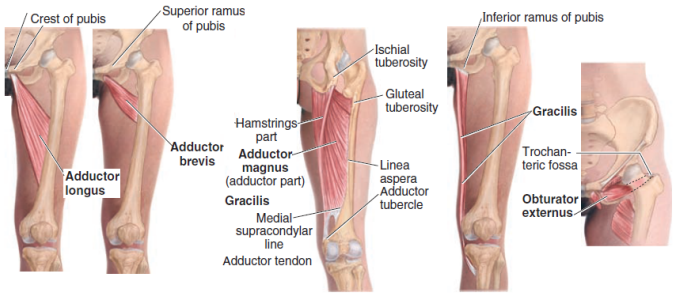

STRUCTURES IN ANTEROMEDIAL THIGH

Femoral Triangle

Border	Structure(s)
Superior	Inguinal ligament
Lateral	Sartorius (medial border)
Medial	Abductor longus (lateral border)
Floor	Iliopsoas (lateral) Pectineus (medial)
Roof	Fascia lata, cribriform fascia Subcut tissue

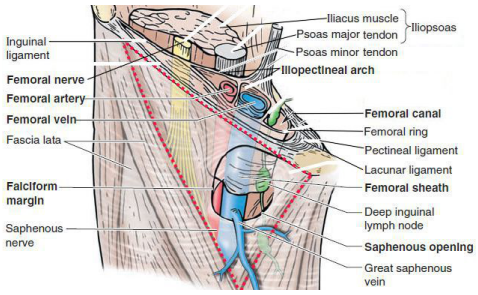

❒ ANTERIOR & MEDIAL THIGH

Retroinguinal space

- Deep to inguinal ligament (ASIS → pubic tubercle)
- 2 compartments (separated by Iliopectineal arch: iliopubic ramus → fascia)
  - Lateral (muscular)

Lateral ↓ Medial

Compartment	Content	
Lateral (muscular)	Iliopsoas	Femoral Sheath
	Femoral Nerve	
Medial (vascular)	Femoral artery	
	Femoral vein[1]	
	Deep inguinal nodes & vessels[2]	
Unnamed	Pectineus	

[1]Including great saphenous and deep femoral branches
[2]In femoral canal

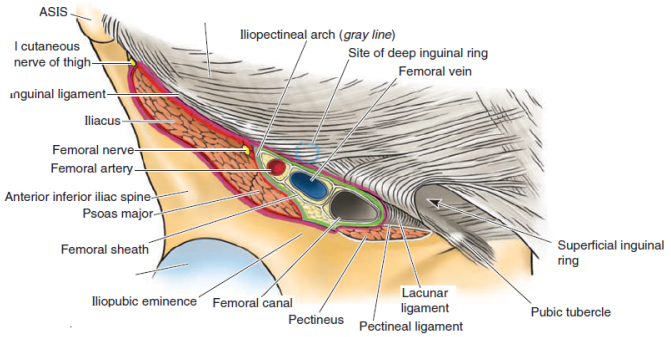

Femoral Sheath

- Originates from transversalis & Iliopsoas fascia
- Terminates when blends with vessel adventitia
- 3 compartments for structures: lateral (A), intermediate (V), medial (Femoral Canal)

Femoral Canal

- Allows femoral vein to expand as required
- Carries lymphatics and fat

Border	Structure
Superior	Femoral septum[1]
Inferior	Saphenous opening
Lateral	Intermediate compartment of femoral sheath
Posterior	Pectineus
Medial	Lacunar ligament
Anterior	Inguinal ligament

[1]extraperitoneal fatty tissue & parietal peritoneum

Femoral Hernias

- Peritoneum → femoral ring → femoral canal → saphenous opening
- More common in females

Adductor Canal

- Apex of femoral triangle → adductor hiatus (on tendon of adductor Magnus)
  (Medial to supracondylar ridge)
- Contents: femoral artery, vein, saphenous nerve

Border	Structure
Anterior/Lateral	Vastus medialis
Medial	Sartorius
Post	Adductor longus & Magnus

Femoral Nerve (L2-4)

- Descends Posterolateral to psoas major
- Enters femoral triangle along middle of inguinal ligament
- Divides into branches that ***supply anterior thigh & hip & knee***
- Terminal branch = ***saphenous nerve***
  - Branches before entering fem triangle
  - Descends lateral to femoral sheath
  - Joins artery & vein in adductor canal
  - Goes superficial through ***Sartorius & Gracilis***
  - ***Supplies skin to Anteromedial knee/leg/foot***

FEMORAL ARTERY

Artery	Origin	Course
Femoral	Ext iliac distal to ing ligament	Femoral triangle → Adductor canal Terminating in ***adductor hiatus*** (as popliteal) Supply: ant/medial thigh
Deep artery of thigh	Largest branch 1-5cm below ing ligament	Descends deep btwn Pectineus & adductor longus Descends post to add longus (medial side of femur) Supply: ant compartment
Medial circumflex	Deep artery just after it branches from femoral	Medially btwn Pectineus & Iliopsoas to gluteal region Supply: ***head & neck of femur***[1]
Lateral circumflex		Laterally deep to Sartorius/rectus femoris Supply: ant gluteal, lateral femur
Obturator	80% Internal iliac 20% inf epigastric	Though Obturator foramen → Medial compartment of thigh Anterior and posterior branches (to adductor brevis) Supply: adductor muscles, ***head of femur***[2]
Proximal branches	Superficial epigastric Superficial circumflex iliac Superficial & deep ext pudendal	

[1]Via posterior retinacular branches
[2]Via branch of posterior Obturator branch

Cruciate Anastomosis

- Medial & Lateral circumflex femoral ←→ inferior gluteal & 1st perforating artery
- Allows collateral flow if femoral artery compromised

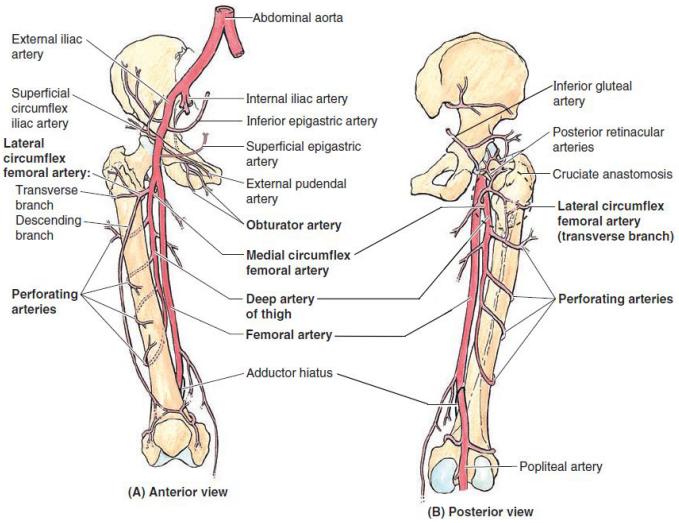

FEMORAL VEIN

- Starts at adductor hiatus (from popliteal vein)
  Relation to femoral artery
  - *Distal: posterolateral*
  - *Mid: posterior*
  - *Prox:: medial*
- Deep branches and great saphenous veins join 8cm below inguinal ligament (still in triangle)
- Becomes ext iliac vein after inguinal ligament

❒ GLUTEAL & POSTERIOR THIGH

GLUTEAL

Border	Structure
Superior	Iliac crests
Inferior	Gluteal folds
Lateral	Iliac crest concaving to greater trochanter

Gluteal Ligaments
- Posterior sacroiliac ligament → sacrotuberous ligament → covers sciatic foramen
- Sciatic foramen
  - Greater & Lesser (split by sacrospinous ligament)
  - Greater carries vessels and nerves to gluteal region

Muscles: Gluteal (NB same compartment)

Superficial

Glut Maximus	Post to post gluteal line[1] + sacrum/coccyx/sacrotuberous ligament	Iliotibial tract[2] + gluteal tuberosity	Inf gluteal	Extend Assist lat rotation
Glut Medius	Btwn ant/post gluteal line[1]	Greater trochanter femur (lat)	Sup gluteal	Abduct, medial rotation (TF Lata probably flexes only)
Glut Minimis	Btwn ant/inf gluteal line[1]	Greater trochanter femur (ant)		
Tensor Fascia Lata	ASIS + ant iliac crest	Iliotibial tract3		

[1]Of posterior ilium
[2]Superficial 3/4, inserts into lateral condyle of tibia
[3]Attaches to anterolateral tubercle of tibia

Deep

Piriformis[3]	Ant sacrum[2] + sacrotuberous ligament	Greater trochanter femur (sup)	Rami S1,2	La rotate extended thigh Abduct flexed thigh Steady head
Obturator internus	Obturator membrane (post)[4]	Greater trochanter femur (sup)	Obt int	
Superior Gemelli	Ischial spine			
Inferior Gemelli	Ischial tuberosity		Quadratus	
Quadratus femoris	Ischial tuberosity	Quadrate tubercle[1]		La rotation

[1]on intertrochanteric crest
[2]through ***greater sciatic foramen***
[3]Orientating muscle in that superior = sup gluteal vessels and nerves – same for inf
[4]through ***lesser sciatic foramen***

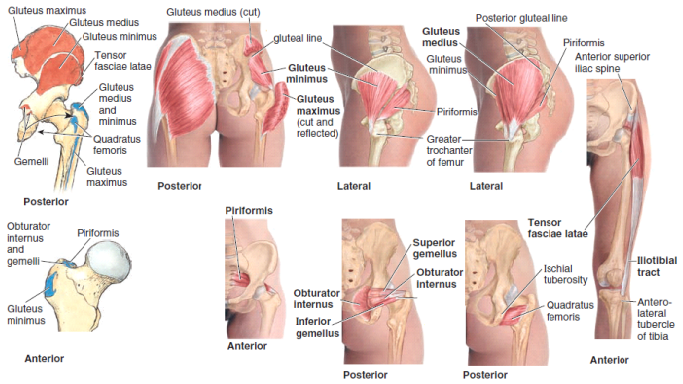

Bursae
- Trochanteric: over greater trochanter
- Ischial: over ischial tuberosity
- Gluteofeomral: attachment of Vastus lateralis

POSTERIOR THIGH

Semitendinous	Ischial tuberosity	Medial Sup Tibia[1]	Sciatic (tibial)	Extend incl trunk Flex and rotate les laterally (when knee flexed)
Semimembranous		Post med condyle tibia[2]		
Biceps femoris		Lateral head of fibula(split by knee collateral ligament)		
Long head				
Short head	Linea aspera Lateral supracondylar line		Sciatic (common fib)	Flex and rotate leg laterally Extend thigh

[1]With Gracilis & Sartorius
[2]2 other parts exist: 1. blends with pop fascia 2. Reinforces intercondylar part of jt capsule

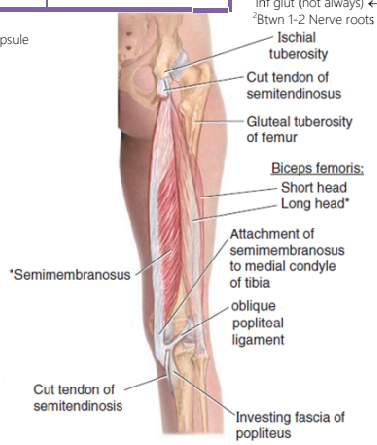

NEUROVASCULAR STRUCTURES

Nerves

Thigh: From Spinal Roots/Cutaneous

Clunial	
Superior	L1-3 post ramus → lat cut branch → Inferolateral across iliac crest Dist: superior buttock (to tubercle of iliac crest)
Middle	S1-3 post ramus → through sacral foramina → gluteal region Dist: sacrum + adj buttock
Inferior	S2-3 ant ramus → Post Cut Nerve[1] → inferior border of glut max → ascends superficial it Dist: inferior buttock (to greater trochanter)

[1]to thigh

Thigh: From Sacral Plexus

Sciatic[5]	L4-S3 ant ramus → sacral plexus[1] → post thigh (deep to biceps femoris) → bifurcates @ pop fossa into tibial& fibula branches Dist: ***Post compartment thigh muscles, all leg and foot muscles, skin of leg & foot (mostly), all joints of lower limb***
Post Cut Nerve[2]	S1-3 ant ramus → Sacral Plexus[1] → emerge @ inf border glut max (in deep fascia) → descend deep to fascia lata Dist: Inf clunial branch & perineal branch (post thigh, pop fossa, lateral perineum, med thigh)
Superior Gluteal	L4-S1 ant ramus → sacral plexus[3] → btwn glut med/minimus (*with sup glut artery*) → tensor fascia lata Dist: ***Glut medius/minimus + Tensor Fascia lata***[4]
Inferior Gluteal	L5-S2 ant ramus → sacral plexus[1] → deep to glut max Dist: ***Glut max***
Nerve to Quadratus femoris	L4-S1 ant ramus → sacral plexus[1] → deep to sciatic nerve Dist: ***hip jt, inf gemellus, quad femoris***
Pudendal[6]	S2-4 ant ramus → sacral plexus[1] → post to sacrospinous lig → through lesser sciatic foramen Dist: perineum only
Nerve to Obturator internus	L5-S2 ant ramus → same as pudendal Dist: ***sup gemellus, obt int***

[1]→ greater sciatic foramen (inf to piriformis) – most lateral structure in foramen
[2]to thigh
[3]→ greater sciatic foramen (***SUPERIOR*** to piriformis)
[4]Sup branch (medius), Inf branch (all 3 structures)
[5]Made up of ***tibial nerve*** (anterior division of ant ramus) and ***fibular nerve*** (post division of ant ramus) – sep in distal thigh
[6]Most medial structure in greater sciatic foramen

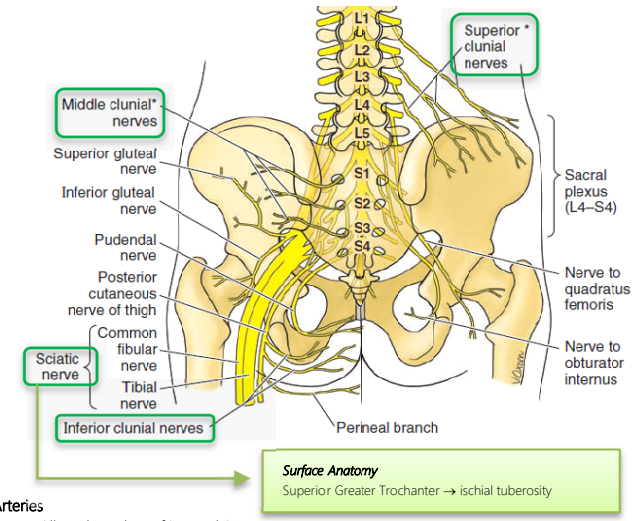

Arteries
- All are branches of internal iliac artery

Artery	Course/Dist
Superior Gluteal	Greater sciatic foramen (***sup*** to piriformis) → superficial & deep branches ←→ inf gluteal, medial circumflex femoral Dist: Superficial – ***glut max*** Deep – ***glut med, min, tensor fascia lata***
Inferior Gluteal	[2]Greater sciatic foramen (***inf*** to piriformis) → descends medial to sciatic nerve ←→ ***cruciate anastomoses***[1] Dist: ***glut max, obt int, quad femoris, sup hamstrings***
Internal pudendal	Greater sciatic foramen → post to ischial spine → lesser sciatic foramen Dist: ***perineal muscles, external genitilia***
Perforating	Terminal/Branch of deep → perforates adductor magnus Dist: ***Central hamstrings, Vastus lateralis (terminal branches)***

[1]Inf glut (not always) ↔ deep femoral (1st branch) ↔ medial & lateral circumflex
[2]Btwn 1-2 Nerve roots

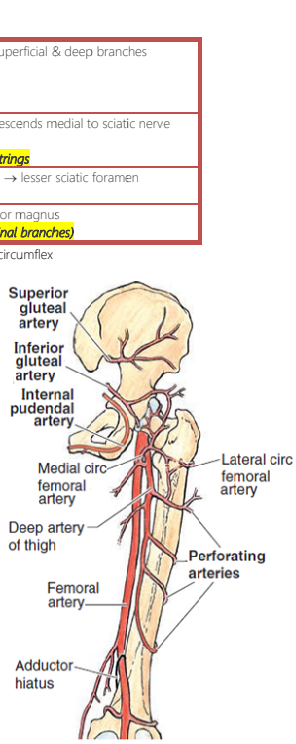

LOWER LIMB

❒ GLUTEAL & POSTERIOR THIGH

Veins

- Gluteal veins (inf/sup – to piriformis) → greater sciatic foramen → femoral v
- Internal pudendal vein follows nerve & artery (lesser → greater → femoral v with inf gluteal)

Lymphatics

Deep Tissues
- Sup/inf gluteal nodes
- It/Ext/Common iliac nodes
- Lateral lumbar nodes (arterial/caval)

Superficial Tissues
- Superficial inguinal nodes
- External iliac nodes

❒ POPLITEAL FOSSA

POPLITEAL REGION

Border	Superficial	Deep
Superolateral	Biceps femoris	*Supracondylar line*
Superiomedial	Semimembranosus, tendinosus	
Inferolateral & medial	Heads of gastrocnemius	*Soleal line*
Posterior	Skin & Pop fascia	
Floor	Popliteal surface of femur, post jt capsule, pop fascia over popliteus	
Roof	Pop Fascia[1] incl small saphenous, post cutaneous nerve to thigh, medial & lateral sural cutaneous nerves	

[1]cont of fascia lata and cont as deep fascia of leg

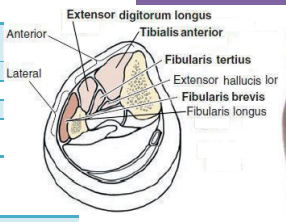

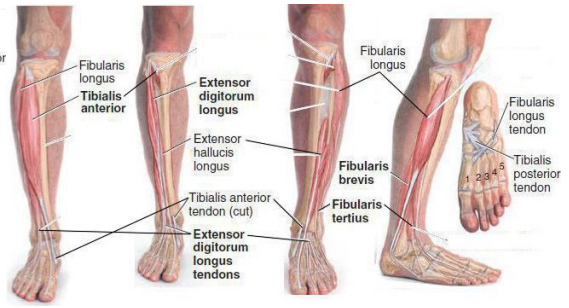

Superficial	Type	Structure	Course
↓	*Nerves*	Tibial	Medial to Common fib Stays along median axis Branches to soleus, gastrocnemius, plantaris, popliteus Branches as sural communicating[1]
		Common Fib	Medial border of biceps femoris Passes superficial to lat head of *gastrocnemius* → out Terminates as it wraps around head of fibula
		Post cut nerve of thigh	Only most inferior branches
	Veins	Popliteal	Cont as femoral vein through adductor hiatus Terminates at inf border of *popliteus* as posterior tibial Receives from small saphenous Ascends superficial to artery
	Artery	Popliteal	Cont of femoral a. through adductor hiatus Terminates over *popliteus* as ant/post tibial a.
Deep		Genicular branches[2]	Participates in Genicular anastamsoses[3]

[1]Joins sural comm of fibular = sural nerve
[2]SL, SM, Middle, IL, IM branches (5) supply knee capsule/ligaments
[3]Genicular branches of popliteal a. +Desc Genicular a. (branch of femoral) + Desc branch f lat femoral circumflex + Ant tibial recurrent

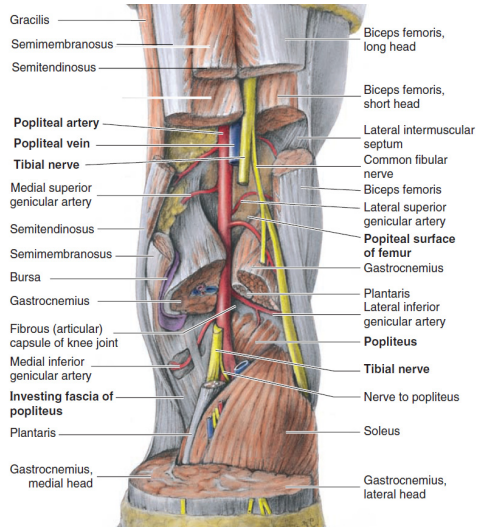

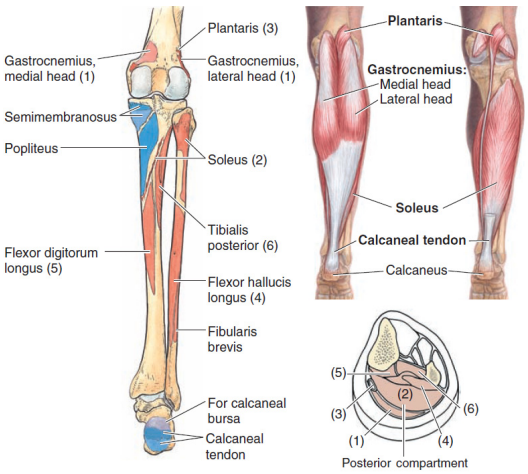

❒ LEG

ANTERIOR COMPARTMENT OF LEG (DORSIFLEXORS)

Tibialis Anterior	Lat condyle & sup lat ½ tibia/IOM	Med/inf medial cuneiforms + base 1st MT	Deep fibular	Dorsiflex ankle Invert foot[1]
Ext digitorum longus	Lateral condyle & sup med ¾ fibula	MP, DP of 2-5 digits[2]		Dorsiflex ankle Extend digits 2-5
Ext hallucis longus	Mid ant fibula & IOM	Ant base 1st DP		Dorsiflex ankle Extend digit 1
Fibularis tetrius	Inf ant 1/3 fibula & IOM	Ant base 5th MT		Dorsiflex ankle Eversion

[1]With Tibialis posterior
[2]Middle band inserts here. ***Extensor expansion:*** lateral bands converge and insert into base of MP

LATERAL COMPARTMENT OF LEG (EVERTORS)

Fibularis longus	Head + Sup 2/3 lat fibula	Base 1st MT & medial cuneiform	Sup fibular	Eversion Plantarflexion (weak)
Fibularis brevis	Ing 2/3 ;at fibula	Ant base of 5th MT tuberosity		

POSTERIOR COMPARTMENT

- Superficial & deep separated by ***transverse intermuscular septum*** (distally forms ***flexor ret.***)
- Supplied by tibial nerve and posterior tibial and fibular vessels (though not in compartment)

Superficial

Gastrocnemius				
Lateral Head	Lat condyle femur	Post surface calcaneus[3] (via calc tendon)	Tibial nerve	Plantarflex ankle[1] Flex leg @ knee
Medial Head	Pop surface femur			
Soleus	Fibula: Post head & ¼ sup Tibia: Soleal line[4]			Plantarflex ankle[2]
Plantaris	Lat supracondylar line & oblique pop ligament			Plantarflex (weak)

[1]When knee extended
[2]Indep of knee, Main plantarflexor (normal activity vs gastrocnemius for stress activity)
[3]Calc tuberosity
[4]Forms tendinous arch of soleus (tibial artery and nerve exit)

Deep

Popliteus	Lat condyle of femur	Post lat tibia sup to Soleal line	Tibial Nerve	Flex knee (weak) Medial rotates (unplanted) Support PCL
Flexor Hallucis Longus	Post 2/3 fibula & IOM[1]	Base f 1st DP		Flex 1st digit Plantarflex (weak) Arch: Med/Long
Flexor Digitorum Longus	Post 2/3 tibia [1]	Base of 2nd to 5th DP		Flex 2nd-th digits Plantarflex Arch: Long.
Tibialis Posterior	Post medial prox 1/3 tibia below Soleal line	Navicular (tuberosity)[2] Base 2nd-4th MT		Arch: Med/Long Plantarflex Invert foot

[1]Distal tendons criss cross in sole of foot
[2]And to a lesser extent: Cuneiform, Cuboid, Sustentaculum tali of calcaneus

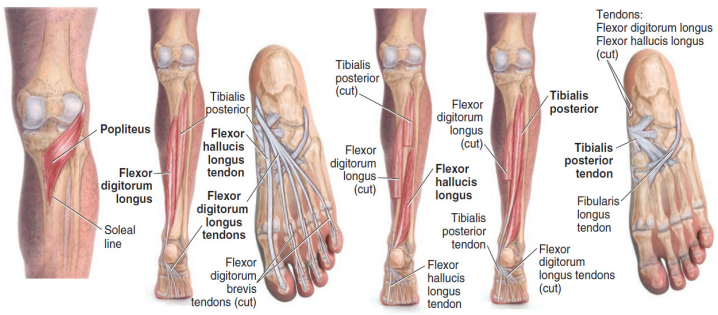

LOWER LIMB

❒ LEG

NERVES OF LEG

Saphenous	Femoral nerve → descends with great saphenous vein Dist: skin to medial ankle/foot
Sural	Off both tibial and common fibular nerves[3] → btwn head of gastrocnemius → superficial mid leg → descends with small saphenous → inf to alt malleolus Dist: skin to post & lateral leg, lateral foot
Tibial	Sciatic → Pop fossa[2] → over popliteus → deep to Tendinous arch of soleus → over Tibialis post → btwn FHL & FDL @ medial malleolus → med & lat plantar nerves Dist: *posterior leg muscles and knee jt*
Common fibular	Sciatic → pop fossa → medial border biceps femoris → winds around head/neck fibula Dist: skin post lat leg (via *sural cut nerve*), *knee jt*
Superficial fibular	Common fib → branches at neck of fibula → follows lat compartment → subcut 2/3 down Dist: *fib longus & brevis*, skin to distal 1/3 ant leg/dorsum foot
Deep fibular	Common fib → branches at neck of fibula → through ext dig longus → follows IOM[1] → foot Dist: *ant* leg muscles, dorsum foot, skin of 1st interdigital cleft

[1]With tibial artery | [2]With pop artery
[3]Medial sural cutaneous nerve, sural communicating branch of common fibula nerve

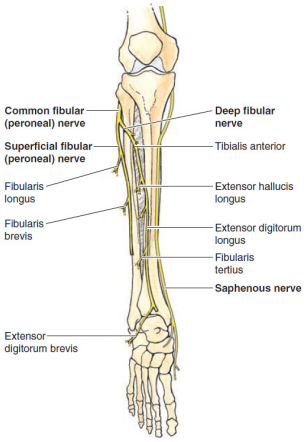

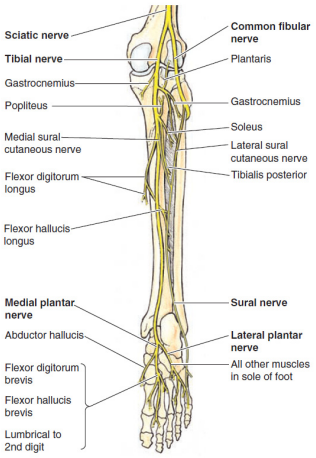

ARTERIES OF LEG

Artery	Origin	Course
Popliteal	Cont of femoral artery @ adductor hiatus	Divides @ inf popliteus border → ant/post tibial a. Dist: sup/mid/inf Genicular arteries → knee
Anterior Tibial	Popliteal → btwn tib/fib → ant compartment → descends on IOM btwn TA & DL	Dist: Ant compartment leg, *proximal lateral compartment*
Dorsalis Pedis	Cont of ant tibial (1st branch → deep palmar artery → plantar arch	Dist: dorsum foot
Posterior Tibial	Popliteal → deep to tendous arch of soleus → branches immediately after into fibular & nutrient artery of tibia → post to medial malleolus btwn TP & FDL → terminates distal to retinaculum as medial/lateral plantar a.	Dist: *Post/Lat compartments of leg*. Knee (via circumflex fibular)
Fibular	Post tibial → post compartment	Dist: Post compartment leg, *distal lateral compartment*

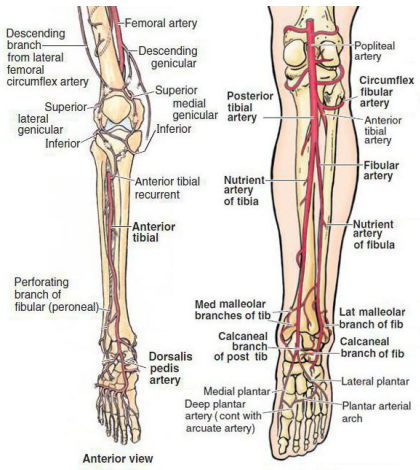

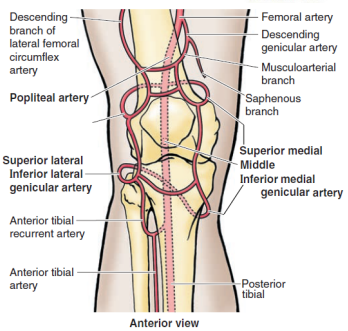

❒ FOOT

SKIN & FASCIA

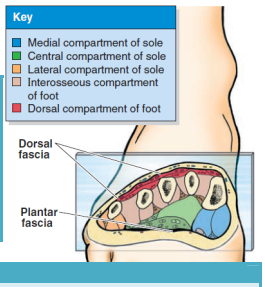

DEEP FASCIA	
Dorsum	• *deep fascia of the dorsum of the foot* • Thin | cont with *inferior ext retinaculum*
Post/Lat	• *plantar fascia* • Central part forms *plantar aponeurosis* • Over MCs reinforced by *superficial transverse metatarsal ligaments* • Intermucuscular sept extend from aponeurosis → compartments

COMPARTMENT	Content
Medial	Abductor hallucis, flexor hallucis brevis, flexor hallucis longus tendon, medial plantar nerve & vessel
Central	Flex dig brevis, flex hallucis/digitorum longus, quadratus plantae, lumbricals, adductor hallucis, lateral plantar nerve & vessels
Lateral	Abductor and flexor digiti minimi
Interosseous	*Only in forefoot* Metatarsals, dorsal & plantar Interosseous, deep plantar and metatarsal vessels
Dorsal	Btwn dorsal fascia & tarsal Ext hallucis brevis, ext digitorum brevis

MUSCLES

1ST Layer

Abductor Hallucis	Medial tubercle of tuberosity of calcaneus, flex ret, plantar aponeurosis	Medial base 1st phalanx	Medial Plantar	Abduct/flex 1st digit
Flex Digitorum Brevis	Medial tubercle of tuberosity of calcaneus, plantar apo, intermuscular septa	Bilateral middle phalanx digits 2-5		Flex 2-5 digits
Abductor digiti minimi	Medial and lateral tubercle of tuberosity of calcaneus, plantar apo, intermuscular septum	Lateral base 5th phalanx		Abduct/flex 5ht digit

2nd Layer

Quadratus plantae	Medial/lateral calcaneus	Post/lat tendon of FDL	Lateral plantar	Help FDL[1]
Lumbricals	FDL tendon	Medial aspect digits 2-5	Medial plantar nerve Lateral plantar nerve	Flex PP, extend MP & DP

[1]Flex lateral 4 digits

3rd Layer

Flexor hallucis brevis	Cuboid & lateral cuniforms	Bilateral base of PP digit 1	Medial plantar	Flex 1st PP
Adductor hallucis		Convrge on lat base of 1st PP	Deep branch of lat plantar	
Oblique head	Base MT 2-4	Base of PP of 5th	Superficial branch of lat plantar	Adduct Arch: transverse
Transverse head	Plantar lig of MTPJ			
Flexor digit minimi brevis	Base 5th MT			Flex 5th PP

4th Layer

Plantar Interossei	Base/medial MT 3-5	Medial base digits 3-5	Lat plantar nerve	Adducts 2-4 Flex MTPJ
Dorsal Interossei	Adj metatarsals 1-5	Medial prox 2nd PP		

Dorsum

Ext digitorum brevis	Calcaneus, talocalcaneal ligament	Long exten. tendon 2-5	Deep fibular	EDL assist @ MTPJ, IPJ
Ext hallucis brevis	Ext dig brevis	Base of 1st digit		EHL assist 2 MTJ

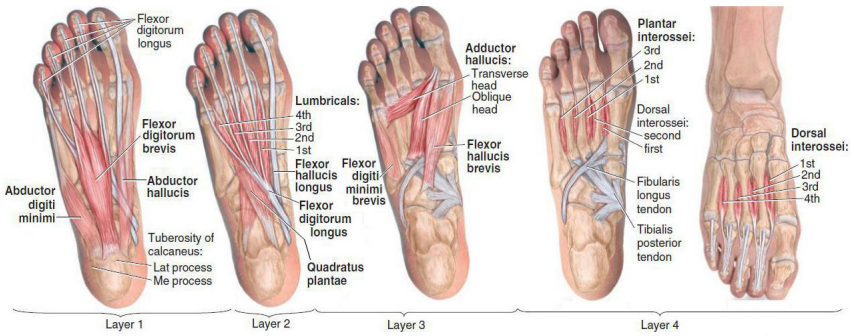

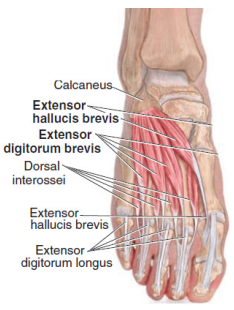

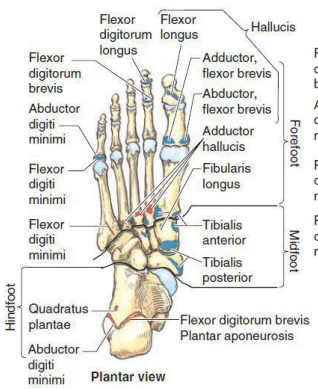

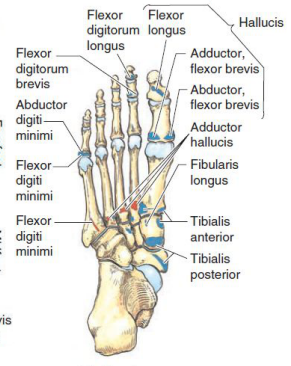

LOWER LIMB

❒ FOOT

NERVES

Saphenous (1)	Femoral → triangle → ant to med malleolus (with great saphenous) → medial foot *Dist: skin medial foot to head of 1st MT*
Superficial Fibular (2)	Common fibular → goes superficial in distal 3rd of leg → ***medial/intermediate dorsal cut nn.*** → ***dorsal digital nerves*** *Dist: dorsum foot & digits (not lat 5th or adjoining sides of 1 & 2)*
Deep Fibular (3)	Common fibular → deep to ext retinaculum → dorsum *Dist: **ext dig brevis, hallucis longus, T/M Jt**, skin of adjoining sides of digits 1 & 2*
Medial plantar (4)	Terminal branch of tibial → btwn abductor hallucis & FDB → musc & cut branches *Dist: skin medial sole & digits 1-3, **abductor hallucis, FDB, FHB, 1st lumbricals***
Lateral plantar (5)	Terminal branch of tibial → btwn quadratus plantae & FDB → superficial & deep branches Dist: skin to mostly rest of sole, ***quadratus plantae, abductor digit minimi, digiti minimi brevis*** *Deep: **plantar & dorsal interossei, lumbricals 3-5, adductor hallucis***
Sural (6)	Tibial & fibular branches → inf to lat malleolus *Dist: lateral aspect of hind/midfoot*
Calcaneal branches (7)	Tibial & Sural branches *Dist: skin on heel*

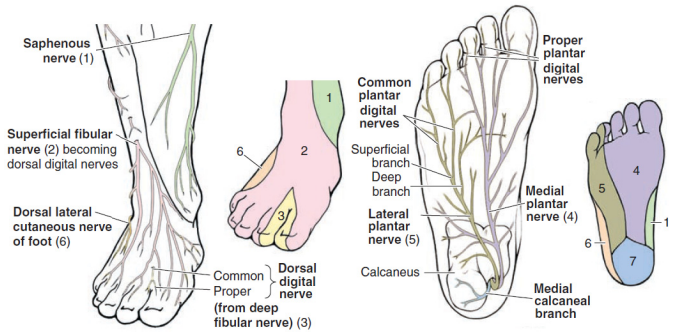

ARTERIES

Artery	Branches	Noteworthy
Dorsalis Pedis (terminal branch ant tibial)	Enters deep to extensor retinaculum btwn EHL & EDL	
	1st dorsal MT a.	Branches at medial base 1st MT Supplies both borders 1st digit and medial 2nd
	deep plantar a.	Branches at medial base 1st MT Deep plantar anastomoses with ***lateral plantar → deep plantar arch***
	Arcuate	Branches laterally in distal midfoot → Anastomoses with lateral tarsal Gives off dorsal MT a. To remaining digits
	Lateral Tarsal	Branches over talus descending laterally under EDB → Anastomoses with arcuate
Plantar Artery (terminal branch post tibial)	Divides deep to flexor retinaculum which pass deep to AH (branches accompany veins)	
	Medial Plantar	Deep branches early on supply great toe Superficial branches run to 1st MT and anastomose with lateral or deep plantar a.
	Lateral Plantar	Descends laterally → Curves medially to anastomose with deep plantar a. Gives off plantar MT a to remaining digits

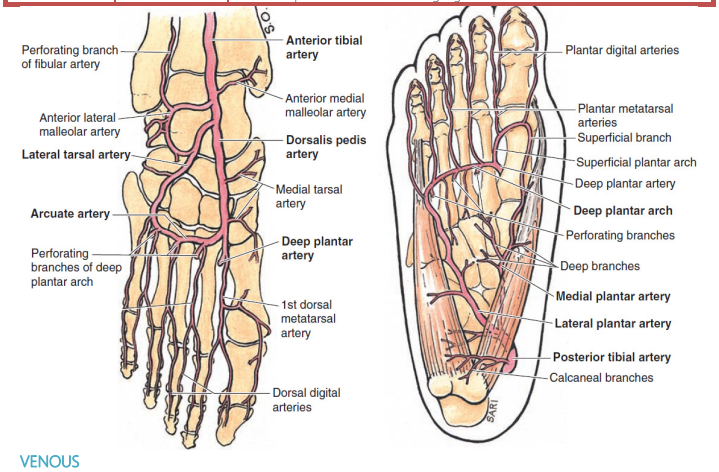

VENOUS

- Deep & superficial veins (superficial are main drainage)

Dorsum (Superficial) *Perforating* ↓ *Dorsal MT* ↓ *Dorsal venous arch*

Plantar (Deep) *Perforating* ↓ *Plantar venous network*

Common *Medial or lateral marginal vein* *Great Saphenous*

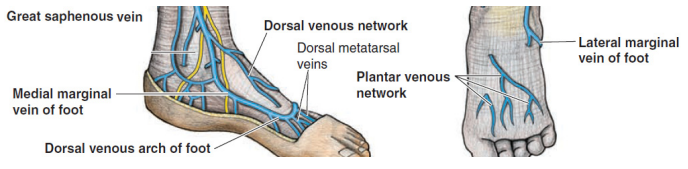

LYMPHATICS

Superficial	Medial → great saph → superficial inguinal nodes → deep inguinal nodes Lateral → small saph → popliteal nodes → iliac nodes
Deep	Follow main veins → popliteal → deep inguinal

❒ JOINTS

HIP

ARTICULAR SURFACE	
BALL	Head of femur 2/3 in socket
SOCKET	Lunate surface of acetabulum + acetabular labrum + transverse acetabular ligament over Acetabular notch

JOINT CAPSULE	
PROXIMAL	attached to acetabular labrum & transverse acetabular ligament
INFERIOR	attached to intertrochanteric line (free posteriorly)
MEDIAL	Ligament of head of femur contains small artery otherwise not structural

NB Tendons balance out muscles eg weak medial flexors = strong ant ligaments

LIGAMENTS	Position	Attachments	Prevents
Iliofemoral	Ant/sup	AIIS → intertrochanteric line	Prevent hyperextension
Pubofemoral	Ant/inf	Obturator crest → medial Iliofemoral ligament	Prevent over abduction
Ischiofemoral	Posterior	Ischial acetabular rim → med base greater troch	Prevent hyper flexion

MOVEMENTS	Primary Muscle(s)
Flexor	Iliopsoas, adductor magnus (Ant)
Flexion & Adduction	Pectineus, Gracilis, 3 adductor nerves
Abductors & Med rotators	Glut Med/Min
Extensor	Glut Max

- *Flexion/extension, medial/lateral rotation, abduction/adduction, circumduction*
- Range: better hip flexion if ***knee flexed***, posterior extension limited due to ***Iliofemoral ligament***

BLOOD SUPPLY	
Circumflex	Medial, Lateral
Retinacular	Branch of medial circ → head
Obturator	→ acetabular branch

INNERVATION	
Ant	Femoral nerve
Inf	Obturator nerve
Post	Nerve to quadratus femoris
Sup	Gluteal

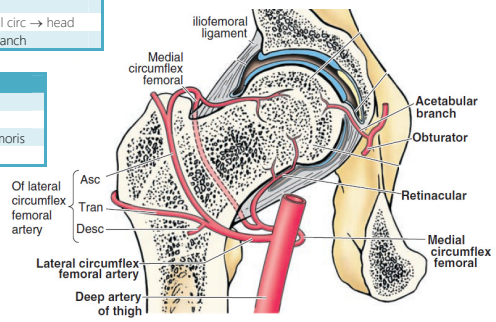

KNEE

Features	
Movements	Flex/Ext, Gliding, Rolling, Rotation
Art Surfaces	1. Lat/Medial Condyles of femur → Tibia 2. Patella → femur
Muscles	Quadriceps
Blood Supply	Genicular anastomoses

JOINT CAPSULE	
Fibrous	• Attachments just overshoot articular margins sup and inf/lat • Inf/post/lat for *popliteus tendon* to pass • Inf/ant replaced by *quad tendon, patella & ligament*
Synovial	• Attaches near articular surface • Lines internal surface of fibrous layer *except for centrally* (where menisci are) • Invests cruciate ligaments posteriorly as an ***infrapatellar synovial fold*** ie not In jt capsule • Suprapatella bursa shares same lining

Extracapsular Ligaments

Ligament	Attachments
Patellar	Quadriceps tendon → patella → tibial tuberosity • ***Patellar retinacular*** attach transversely to stabilise • Tendency to ***displace laterally*** given "q-angle"
Collaterals	
Fibular	Lateral epicondyle → lateral fibula • ***Popliteus*** deep to FCL ∴ not attached to meniscus • Splits tendon of ***biceps femoris***
Tibial	***CAPSULAR***: medial epicondyle femur → medial epi & sup part of medial surface of tibia • Attaches to meniscus • More fragile than FCL
Oblique	Recurrent expansion of Semimembranous: post medial tibial condyle → lateral femoral condyle
Arcuate Pop	Posterior fibular head → spread over post capsule

Intra-articular Ligaments

	Attachment	Prevention	Noteworthy
ACL	***Tibia: anterior***/medial Femur: posterior/lateral	Post displacement of femur on tibia Post rolling ∴ forces on Femur → rupture	Weaker Poor blood supply +ve ***anterior*** draw sign
PCL	Tibia: post/lateral Femur: ant/media Medial to ACL	Ant displacement Hyperflexion Ant rolling ∴ forces on Tibia → rupture	Stronger Usually rupture with fibular/tibial ligament +ve posterior draw sign

- Cruciates are in jt but OUTSIDE synovial cavity
- Medial rotation = ligaments wind up = 10° only
- Lateral rotation = ligaments unwind = 60° (when knee 90°)

Menisci		
Medial	Inserts ant to ACL & Ant to PCL ***Attached to TCL***	∴ less mobile NB More likely to tear with medial rotation
Lateral		Popliteus tendon bifurcates – posterior branch to lat meniscus Not likely to tear due to mobility but lateral rotation can do it

- Meniscal or PCL tears usually occur in conjunction with TCL/FCL tears
- ***Coronary ligament*** attaches menisci outer edge to tibial condyle
- ***Transverse ligament*** attaches intra-menisci anteriorly but ***post meniscofemoral ligament*** hold medial & lat together

LOWER LIMB

❒ JOINTS

Movements	Degree	Primary	Secondary	Noteworthy
Extension		Quad Fem	Tensor fascia	Best when hip extended
Flexion	Hip ext(120) Hip flex (140) Passive 160	Hamstrings + short head biceps	Gracilis, Sartorius, gastroc, pop	
Medial Rot	Knee ext(5) Knee flex(10)	Flexed: semi's Ext: pop	Gracilis, Sartorius	WB: pop lat rotate femur NWB: pop med rotate patella
Lateral Rot	30	Flex: Biceps femoris		Tensor fascia

- Flex/ext (rotate when flexed)

INNERVATION	
Anterior	Femoral
Posterior	Tibial
Lateral	Common fibular

Knee Aspiration: Triangle of safety	
Anterolateral	tibial tubercle
lateral	epicondyle of femur
apex	of patella

Bursae	Location	
Suprapatella	Femur || quad tendon	
Popliteus	Popliteus || lateral tibial condyle	
Anserine	Separates from tibia/TCL from muscles (Sartorius, Gracilis, semitendinosus)	Communicates with synovial cavity of knee
Gastrocnemius[2]	Deep to medial origin of gastroc tendon	
Semimembranous[2]	Btwn gastroc head & semi membranous tendon	
Subcut prepatellar[1]	Skin & Ant patella	Skin moves on patella
Subcut intrapetllar	Skin & Tibial tuberosity	
Depp infrapatellar	Patellar ligament → ant surface tibia	Infrapatellar fat pad sep from art surface

[1] Bursitis = housemaid's knee
[2] More likely to contribute to popliteal cysts by herniating through fibrous layer of joint capsule

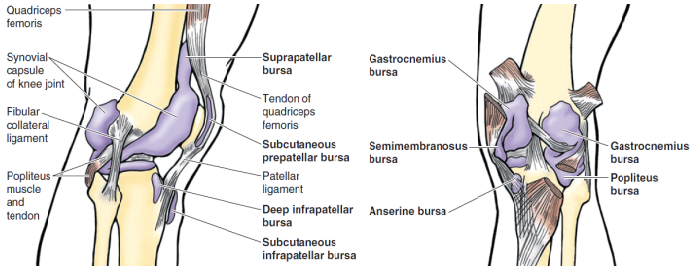

TIBIOFIBULAR

- 2 joints: tibiofibular jt (sup) and tibiofibular syndesmosis (inf)
- Interosseous membrane joins

Tibiofibular

- Plane
- Ant/post ligament of fibular head
- Popliteus tendon behind with popliteus bursa on lateral condyle
- Movement: slight during dorsiflexion
- Blood: inf Genicular, ant tibial recurrent
- Innervation: common fibular, nerve to popliteus

Tibiofibular syndesmosis

- Compound fibrous joint
- Complex of ***distal tibia, fibula, Interosseous membrane & tibiofibular ligaments*** (ant, Interosseous, post)
- Ligaments: Interosseous tibiofibular → ant & post (→ inferior transverse)
- Movement: slight during dorsiflexion
- Blood: fibular (medial), ant/post tibial (lateral)
- Innervation: deep fib, tibial, saphenous

ANKLE

MALLEOLAR MORTISE – Art Surfaces	
Lateral	malleolus (distal fibula) ↔ lateral talus
Medial	malleolus (distal tibia) ↔ medial talus
Inferior	Tibia ↔ superior talus

NB Talus is wider anteriorly ∴ ***Dorsiflexion*** pushes talus back into confined space **= *more stable*** vs.
Plantarflexion pulls talus out of space = ***less stable*** = ***injuries***

Potts # = forced eversion = avulsed # distal tibia + # fibula shaft above syndesmosis

LIGAMENTS	
LATERAL	***Ant talofibular:*** lat mall → neck of talus, weak
	Posterior talofibular: medial border of lat mall → lateral tubercle of talus
	Calcaneofibular: distal fibula → Lateral calcaneus
	More common in ankle sprains (esp ant talofibular)
MEDIAL	Unlike lateral – is ***single ligament*** with subdivisions: ***tiobionavicular, tibiocalcaneal ant/post tibiotalar***

- Movements: Dorsiflexion/Plantarflexion with some ab/add/in/ev
- Blood Supply: Fibular and ant/post tibial
- Innervation: Tibial, deep fibular

FOOT

NB Important Intertalar Joints - Rest are tightly bound by ligaments = little movement

HIND/MIDFOOT

Joint	Type	Noteworthy	
Subtalar (talocalcaneal)[1]	Plane synovial	Ligaments: medial, lat, post, ***Interosseous talocalcaneal ligaments*** (strong)	Inversion/Eversion
Transverse Tarsal Jt			
Talonavicular[2]	Ball & socket	Plantar calcaneonavicular ligament supports head of talus	Rotate on long axis to augment inversion/eversion
Calcaneocuboid	Plane synovial	Dorsal calcaneus + dorsal cuboid	

[1] Surgical Subtalar jt = Subtalar + talocalcaneal part of talocalcanavicular joint since can't work indep
[2] Of talocalcanavicular joint

FOREFOOT

Joint	Type	Noteworthy	
MTPJ	Condyloid synovial	***Collateral & plantar ligaments***	Flexion, extension with some abd/add/circ
IPJ	Hinge synovial		Flexion, extension

MAJOR LIGAMENTS	
Plantar calcaneonavicular	Medial calcaneus → posterior Navicular Support head of talus & forms Lcngitudinal arch of foot
Long plantar	Plantar calcaneus to groove on cuboid + base of MT Longitudinal arch of foot
Plantar Calcaneocuboid	Ant/inf calc → inf cuboid (ie btwn above 2 ligaments)

ARCHES	
Longitudinal arch	
Medial	higher, more important, ***calc, tal, Navicular, cuniforms, 3 MT***
	• Tibialis tendon (attaching to 1st MT & medial cuneiform) reinforces
	• Fibularis longus also supports
Lateral	• Rests on ground during standing/walking
	• ***Calcaneus, cuboid, lateral 2 MT***
Transverse arch	
	• Formed by distal row of tarsals – ***cuboid, cuneiforms & corresponding bases of MT***
	• Origin and termination in longitundal arch
	• ***Fibularis longus*** & ***Tibialis POSTERIOR*** (both cross the sole) help support

Weight bearing points
1. Tibia → talus → calcaneus
2. Sesamoid of 1st MT & head of 1st MT
3. Head of 3rd – 5th MT

Movements

- In general, names of muscles do only that action

Exceptions
1. ***Interossei:*** flex, dorsal abducts, plantar adducts all on MTP
2. ***Lumbricals:*** flex MTP
3. ***Quadratus Plantae:*** Flex IPJ